

## CASE REPORTS

# Simultaneous Presentation Of Both True And False Aneurysm In The Infrarenal Aorta

M Townend, A Keightley, BA Price

### ABSTRACT

**Interventional radiology has resulted in a reduced need for bypass procedures for aorto-occlusive disease. However, there are still indications for surgery of this type, which carries with it a small but significant morbidity and mortality. False aneurysms are well described following such procedures but with the development of inert, strong and non-absorbable materials they are becoming less common. This paper describes the acute presentation of a false aneurysm of the aorta following an aorto-iliac bypass where true aneurysmal change had taken place in the area of the anastomosis.**

### Keyword

*Aorta, False Aneurysm, True Aneurysm*

### Introduction

Elective abdominal aortic aneurysm repair is commonplace in present day surgery. However, half a century ago patients with a large symptomatic aneurysm had no real chance of long-term survival. There was no adequate means of repairing the failing aorta although packing the sac with wire cellophane wrapping and ligation had all been attempted (1). It was not until the early 1920's that the forward-looking Rudolph Matas (2) suggested that an artificial means of repairing aortic aneurysms would one day become available. Surgeons initially started using human cadaveric aortas but the prognosis was often unsatisfactory. The grafts tended to thrombose or become aneurysmal themselves. In 1954 Blakemore and Voorhees described the first attempt of a repair using a synthetic graft (3). They were forced to improvise during a shortage of fresh cadaver grafts and fashioned a replacement made from Vinyon-N, a material used in parachute manufacture. Unfortunately, their attempt failed and the patient died from per-operative complications. However, the graft was patent throughout. Elsewhere, other surgeons were also experimenting and the first documented success went to the French surgeon, Charles Dubost, who by using a human autograft, was able to successfully replace the aorta and save his patient's life (4,5). Considerable progress has been made since the introduction of synthetic grafts,

but the method is not without problems. The following case presentation demonstrates a long-term complication, following previously successful surgery for aorto-iliac occlusive disease.

### Case History

Mr JH, a 58-year-old Caucasian man presented to the Accident and Emergency Department with a four day history of severe, dull aching pain of the dorsal spine localised between the shoulder blades. It had become progressively worse from onset and was associated with an episode of vomiting and clamminess. The pain was exacerbated by movement but did not radiate. There was no chest or abdominal pain, or dyspnoea. Nine years previously, he had undergone an aorto-bifemoral bypass for occlusive disease from which he recovered without complication. The Dacron graft had been anastomosed end to side to the infrarenal aorta using continuous 2/0 silk. He is a reformed cigarette smoker having ceased following a myocardial infarction in 1991. His medication comprised of Lacidipine 4 mg to control essential hypertension. There were no other significant vascular risk factors.

Examination revealed an anxious man of slim build able to sit comfortably whilst still. Pulse rate was regular at 78 beats per minute with a blood pressure of 180/100. Heart sounds were normal. The abdomen had a full-length, well healed right paramedian scar. A pulsatile, tender mass was apparent over which, a moderately loud bruit could be heard. A false anastomotic aneurysm of the aorta was diagnosed.

### Investigations

Full blood count, urea and electrolytes, erythrocyte sedimentation rate and amylase were all within normal limits. The chest radiograph and electrocardiogram were also normal. Computerised tomograph (CT scan) confirmed a large false aneurysm of 7 centimetres with evidence of some true aneurysmal disease posteriorly. (Fig 1)

An arteriogram (Fig 2) showed aneurysmal changes in the infrarenal aorta in the region of the anastomosis.

### Operative Findings

The abdomen was entered with a midline incision and the aorta exposed. A 5.5 centimetre mass of white fibrin was

Lt M Townend MB BS  
RAMC  
House Surgeon

Dr A Keightley MRCP  
FRCR  
Consultant Radiologist

Lt Col B A Price MD  
MS FRCS (Ed) FRCS  
RAMC  
Consultant Vascular  
Surgeon  
E-mail:  
Barriep@aol.com

Departments of  
Vascular Surgery and  
Radiology, Ministry of  
Defence Hospital Unit,  
Frimley Park,  
Camberley, Surrey  
GU16 5UJ.

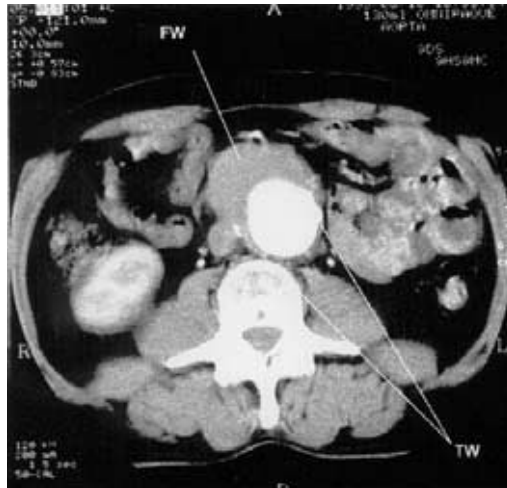


Fig. 1 CT scan showing aneurysmal native aorta with calcification in its true posterior wall (TW) and additional thrombotic material anteriorly (FW).

confirmed in the anterior aspect of the infrarenal abdominal aorta. The proximal limb of the graft was well incorporated by the surrounding tissues and after clamping the fibrin plug was entered. The native aorta was found to have undergone some true aneurysmal change confirming the CT scan and arteriogram findings. The graft was

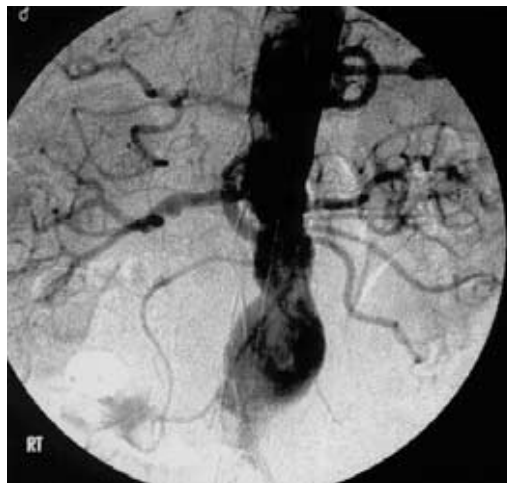

Fig. 2 An arteriogram showing an aneurysm in the region of the anastomosis of the graft that can just be seen as a faint outline inferiorly.

almost completely detached from the aortic wall and this detachment was completed by removal of the remaining silk sutures. A schematic representation of the operative findings is shown at Fig 3.

### Discussion

The false aortic aneurysm in this case was secondary to the disruption of the silk sutures used during the initial aorto-bifemoral bypass. This has been a popular material in the past because of its handling properties. However it is known to degenerate and weaken over time. Inert materials such as polypropylene (Prolene™) which are unaffected by macrophages and tissue enzymes are preferred. In our case,

the heel of the graft was the only part still attached to the aorta. A thick rind of fibrin and the surrounding retroperitoneal tissues formed the flow channel. It is of interest that the crucible of aorta forming the posterior wall of the aneurysm should have gone truly aneurysmal. To our knowledge this has not previously been described.

It has been suggested that end to side anastomosis of aortic grafts suffer a greater number of complications compared to end to end anastomosis. (6) In our case the original anastomosis was an end to side procedure which could well have contributed to the breakdown of the graft suture line and the development of some true aneurysm formation. On repair of the false aneurysm, the graft was converted to an end to end anastomosis.

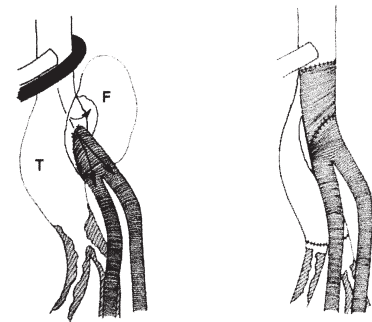


Fig. 3 T represents the true aneurysm and F the fibrin plug. The area between the two is the false aneurysm space through which the blood stream passed across as depicted by the arrows. The diagram on the right represents the anatomy following repair. The left renal vein has been omitted for the sake of clarity.

Open aortic surgery, if successful, is associated with a normal expected life span. The repair has to last many years without failure. It must not be assumed that optimum materials have been used in previous surgery and false aneurysm formation must be excluded in any patient presenting with pain associated with areas of previous arterial synthetic graft anastomoses.

### References

1. Friedman SG. A History of Vascular Surgery. Futura Publishing Company Inc. New York 1989.
2. Matas R. Ligation of the abdominal aorta. *Ann Surg* 1925; **81**:457
3. Blakemore AH, Voorhees AB Jr. The use of Tubes Constructed from Vinyon N Cloth in Bridging Arterial Defects - Experimental and Clinical. *Ann Surg* 1954; **140**: 324-34.
4. Dubost C, Allary M, Oclonomos N. Resection of an aneurysm of the abdominal aorta: Re-establishment of the continuity by a preserved human arterial graft, with results after five months. *Arch Surg* 1952; **64**: 405-9
5. Dubost C. First successful resection of an aneurysm of an abdominal aorta with restoration of the continuity by a human arterial graft. *World J Surg* 1982; **6**: 256-7
6. Adiba TE, Mars M, Robbs JV Choosing the proximal anastomosis in aortobifemoral bypass. *Br J Surg* 1997, **84**, 1416-1418.