

## REGULAR REVIEW

### Varicose Veins – An Old Dog And Some New Tricks

JP Garner, DJ Gerrard

#### Introduction

There are more than 60,000 operations for lower limb varicose veins performed in UK every year (1), with 20% of these for recurrent veins (2). This represents a significant financial and logistic burden to the NHS. Any therapeutic advancement that reduces this load would be highly desirable and this has spawned a plethora of novel strategies to treat varicose veins. Included within this are techniques which aim to eradicate varicosities but preserve a patent Long Saphenous Vein (LSV) for potential future use in arterial bypass surgery. This article provides an overview of current concepts regarding the pathophysiology, assessment and standard treatment of primary varicose veins. It then examines the new techniques vying for primacy and acceptance as the new 'gold standard' for varicose vein treatment.

#### Anatomy

The Long Saphenous Vein (LSV) is the longest vein in the body and follows a fairly constant course as it ascends anterior to the medial malleolus to pierce the cribriform fascia in the groin and there join the femoral vein. It may be duplicated or even triplicated for some, or all, of its course (3). The LSV has numerous perforating branches that connect the superficial to the deep venous system with the majority of these perforators between ankle and knee. At or about the saphenofemoral junction numerous tributary veins join in a highly variable pattern (Figure 1).

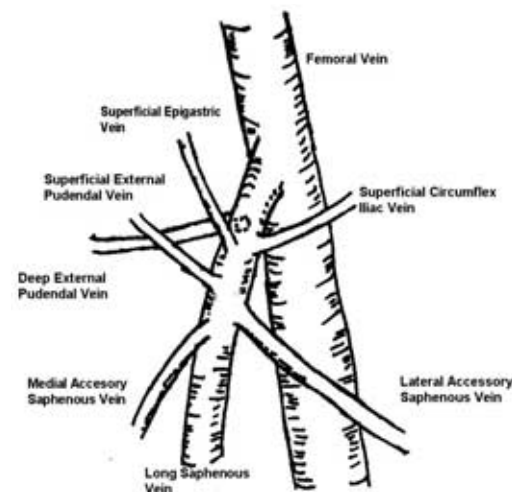


Fig 1. The saphenofemoral junction. At surgery, the long saphenous vein is notable for its many tributaries, whereas the femoral vein is joined by the LSV alone.

The Short Saphenous Vein (SSV) is a continuation of the dorsal venous arch of the foot and ascends with the sural nerve behind the lateral malleolus, running up the midline of the calf and piercing the deep fascia. It usually joins the popliteal vein deep in the popliteal fossa, but the junction is highly variable and indeed may be absent, the short saphenous vein ascending to join the deep femoral vein in the thigh. It may also communicate with the LSV through several perforating branches.

#### Pathophysiology & Complications

The pathophysiology of varicose veins remains poorly understood. It has been considered to be the result of the failure of the proximal venous valves allowing a progressive venous hypertension to develop from above, thereby damaging the descending valves. There is little evidence to support and much to refute such an assertion. It is well known that the distal LSV may become varicose with an intact Saphenofemoral junction (SFJ) (4) and that the vein dilates below the valve, and not above as might be expected (5). It is also unclear as to why the valves become incompetent. It may be that the valves themselves degenerate or, that the supporting vein wall fails, thus making the valve incompetent. There are supporters of both opinions and little good evidence for either. Recent studies have demonstrated infiltrations of monocyte/macrophages around varicose valves (6), alterations in the ratios of collagen subtypes (7), matrix metalloproteinase variations (8) and differences in rates of apoptosis (9). It is impossible to tell whether these observed differences are cause or effect. Similarly, Hollingsworth (10) has demonstrated that the growth of smooth muscle cells (SMC) in the wall of varicose veins is not regulated in the same way as 'normal' SMCs, which may be a further aetiological factor. Whatever the underlying pathophysiology, the considerable influence of heredity should not be overlooked (11).

The problems associated with varicose veins extend beyond mere cosmesis although in some cases this is an important factor. The main complications of lower limb varicose veins are listed in Box 1, although it should be noted that the evidence linking varicose veins with an increased risk of deep venous

Maj JP Garner  
MRCS(Ed) RAMC  
Surgical Research  
Registrar  
Dstl Porton Down,  
Salisbury, Wilts,  
SP4 0JQ  
Email:  
jeffgarner4@hotmail.com

Mr DJ Gerrard FRCS  
(Gen Surg)  
Consultant Vascular  
Surgeon  
Frimley Park Hospital,  
Portsmouth Road,  
Camberley,  
Surrey, GU16 5UJ

thrombosis is not very strong. The management of many of these complications would constitute review articles in themselves and they are not considered here further.

Box 1. Complications of varicose veins.

- Bleeding
- Ankle oedema
- Superficial thrombophlebitis
- Lipodermosclerosis
- Ulceration
- Deep venous thrombosis

**Assessment**

A careful history is essential and should specifically ask about those points presented in Box 2. Examine the standing patient in good light and assess the distribution of varicosities. Clinical examination may be woefully inaccurate (12) and evidence of reflux should be sought using a hand-held Doppler (HHD)(13). By positioning the probe overlying the SFJ and applying and then releasing a calf squeeze, saphenofemoral incompetence (audible reflux greater than 0.5s duration) can be elicited. Sequential testing down the course of the LSV can identify sites of perforator incompetence. The saphenopopliteal junction (SPJ) is assessed in a similar manner. Whilst better than clinical examination (11), HHD itself may be misleading with specificity for SPJ reflux reported as low as 44% in one series (14). Another study reported that HDD assessment in primary varicose veins would have resulted in a quarter of patients receiving inadequate surgery, mostly through missed SPJ incompetence and overall there was a 29% discrepancy between HDD assessment and optimal surgical requirements (15). The authors of that report recommended Duplex scanning for all varicose vein patients and whilst practiced in some units, it is not universally practiced amongst

British vascular surgeons. A more rational use of Duplex assessment in equivocal or recurrent cases is a practicable compromise. Additionally, all patients with a history of (or suggestive of) deep venous thrombosis should be scanned and the vast majority of vascular surgeons also routinely scan suspected SPJ incompetence. Duplex – directional flow Doppler – has revolutionised the treatment of varicose veins since its introduction in the 1960s and is a pre-requisite for many of the novel treatment strategies detailed below. It confirms patency of the deep veins, identifies the sites of incompetent perforators and presents the surgeon with a ‘road-map’ of the miscreant veins. This is especially valuable when re-exploring the groin after recurrence.

**Options For Treatment**

The simplest method of reducing the venous hypertension implicit in varicosities is to wear compression stockings. Surgical class II stockings are designed to provide 30mmHg compression at the ankle (16) and are effective in many instances in relieving the ache associated with varicosities. In those unfit for surgery, they remain the mainstay of treatment. Unfortunately, many people are intolerant of stockings in the long-term because of their unflattering appearance, difficulty in applying them or the discomfort caused by wearing such thick stockings, particularly in hot weather. Primary thread veins, or minor residual veins after surgery, may be dealt with by sclerotherapy using injections of a compound such as 0.5-1% sodium tetradecyl sulphate. Patients should be warned about the risks of extravasation with subsequent pigmentation, bruising and failure to completely eradicate the veins. Sclerotherapy is no guarantee against the emergence of further thread veins and is generally ineffective against large varicosities. The UK standard treatment for symptomatic lower limb varicose veins is surgery. This entails disconnection of the saphenofemoral junction and all its tributaries with flush ligation of the SFJ stump, stripping of the

Box 2. Essential points in the history.

Symptoms	Risk factors
<ul style="list-style-type: none"> <li>● Aching</li> <li>● Bleeding</li> <li>● Ulceration</li> <li>● Interference with daily activity</li> <li>● Ankle swelling</li> <li>● Restless legs</li> <li>● Cosmesis</li> <li>● Night cramps</li> </ul>	<ul style="list-style-type: none"> <li>● Family history of varicose veins</li> <li>● Pregnancy</li> <li>● Use of oral contraceptive pill</li> <li>● Deep Venous Thrombosis</li> <li>● Lower limb Plaster cast</li> <li>● Occupation inc. amount of standing</li> <li>● Previous venous surgery</li> </ul>

LSV to at least the knee and multiple stab avulsions of the remaining varicosities (17). This is usually termed 'high tie, strip and avulsions'. The SSV is usually ligated and divided from its junction with the popliteal vein. Some surgeons prefer not to strip this because of risk of damage to the sural nerve.

### High tie, strip and avulsions

Adequate informed consent must be obtained, including provision of information on scars, paraesthesia and nerve injury, postoperative bruising and potential infection as well as the risk of recurrence, which is usually quoted as a 10% risk at 10 years. Prior to operation the patient should be re-examined whilst standing upright and varicosities marked with an indelible skin marker. The Duplex report should be available for inspection.

With the patient under general anaesthesia, laid supine with 20° of head-down tilt and the legs abducted, the marked leg is prepared and draped exposing it from groin to foot, a small transverse incision is made in the groin overlying the saphenofemoral junction and the superficial fat divided. The Saphenofemoral junction is exposed, all tributaries systematically resected, flush ligated and disconnected. The LSV is opened between clips and a stripper passed distally to the required level where the tip is retrieved through a stab incision and secured to the vein. The vein is usually stripped antegradely, but may be stripped retrogradely. Using a series of tiny stab incisions along the lines of the skin markings the remaining veins are hooked up and avulsed. The leg is wrapped with wool and elastic compression bandaging. The groin wound is closed and dressed. Patients are advised to change the bandaging to compression hosiery the following day and to walk for at least 30 minutes twice daily for two weeks. Most working patients receive between two and four weeks sick leave. Soldiers often receive a period of light duties thereafter. Routine follow up is usually not required.

### Novel Treatments

The renewed interest in less invasive treatments for varicose veins is an attempt to limit the financial implications of extended absence from work after open surgery and potentially preserve the LSV for future harvest and utilisation as an arterial conduit. Up to 28% of patients who would ideally have had a LSV conduit had it stripped at previous varicose vein surgery (18). All these novel technologies show promise but are frustrated by the absence of the long-term follow up required to recommend their widespread adoption.

**Radiofrequency endovenous obliteration:** This has been developed by VNUS Medical Technologies (Sunnyvale, Cali-

fornia) and is known as the Closure technique (19). Under ultrasound guidance the LSV is cannulated at the ankle and a flexible catheter with sheathed radiofrequency electrodes at the tip is passed via the cannula sheath into the vein lumen. The catheter is passed proximally to the level of the SFJ, its position being checked by ultrasound. Saline is injected subcutaneously in the groin to provide a buffer between the LSV and the overlying skin to diminish the likelihood of skin burns; this may be repeated throughout the course of the LSV where it lies particularly superficially. The leg is elevated and exsanguinated. After unsheathing the electrodes and ensuring a good contact with the vein wall, the radiofrequency generator is activated, heating the electrode tips to 85° C. The catheter is then gradually withdrawn down the length of the LSV at a rate of 2.5-3cm per minute to the level of the tibial condyle whilst maintaining good vein-electrode contact. Closure of the venous channel occurs because of shortening of the collagen constituent of the vein wall under the thermal insult. Occlusion of the vein can be confirmed by the colour duplex ultrasound scanner and any non-occluded segments retreated. At completion of treatment, the catheter is withdrawn and a compressive bandage applied.

Patients routinely have the procedure under local anaesthetic and walk out of the surgical centre the same day. Goldman (20) reported return to normal activity within 48 hours for all patients in his small series. A Finnish study (21) comparing the cost of Closure against standard open operation described a mean sick leave duration of 6.5 days in the 'Closure' patients, significantly shorter than the 15.6 days in the 'stripped' group. It concluded that if indirect costs such as time-off-work were included in the analysis then VNUS Closure was cost effective if more than 150 procedures per year were carried out on working patients. Complications appear to be minor and include thrombophlebitis and a mildly tender fibrous cord along the length of the treated vein, requiring only simple analgesia. The incidence of saphenous nerve paraesthesia appears similar between the two groups (21). Minor skin burns may also occur with the Closure system (21). Follow up beyond two years is scarce. A large multicentre study of VNUS Closure reported a recurrence rate of 13.4% at 2 years (22). This system has also been used on 12 patients with recurrent varicosities, and the 10 patients remaining in follow up were free from further recurrence at 12 months (23). Using an endovascular method such as this avoids the frequent morbidity associated with re-exploration of the groin in such circumstances (24).

**Endovenous laser treatment (EVLT):** This is similar in some respects to the VNUS

Closure system in that percutaneous cannulation of the LSV below the knee under ultrasound guidance is followed by introduction of a catheter and heating element. In this instance a bare laser fibre is introduced down an angio catheter (25). Tumescence local anaesthesia is then injected along the entire course of the LSV before heating starts. Energy is delivered by pulsed emission from a diode laser and the catheter withdrawn back to the puncture site. Ultrasound scanning confirms venous occlusion and the patient is then given full-length class II compression stockings. EVLT appears to work by generation of a steam bubble (25) within the vein lumen with internal temperatures of up to 100° C which is the mediator of collagen shortening in the vein wall, which collapses onto itself. Direct impingement of the laser on the vessel wall causes carbonisation, perforation and non-perforating vaporisation, but there appears to be no obvious clinical sequelae. In a small trial from Germany (31 limbs) all limbs demonstrated thrombotic occlusion of the LSV at 28 days after treatment with minimal side effects (25). A larger non-randomized uncontrolled study in the US reported occlusion of the LSV persisting up to a nine month follow up in 89 of 90 legs treated with a 840nm diode laser (26).

**Transcatheter sclerotherapy:** Traditional sclerotherapy, when used for large truncal varicosities, achieves poor results with recanalisation of the sclerosed vessel, recurrence rates of over 50% (27) and significant complications of tissue necrosis following intra-arterial sclerosis and painful thrombophlebitis (28). Transcatheter sclerotherapy (29) again uses ultrasound to locate the LSV around the knee for percutaneous cannulation and positioning of the injection catheter. Once in place, aliquots of 3% sodium tetradecyl sulphate are injected at 3-5cm intervals along the vein from SFJ to entry puncture whilst the SFJ is externally compressed. After catheter removal Class II stockings are worn for a week. In 51 legs treated in this manner, all patients remained free from recurrence with Doppler-proven occlusion of the treated LSV at a mean of 8 months follow up. There were no reported complications (29).

**Foam sclerotherapy:** The putative benefits of sclerotherapy using foams over liquids are increased vein wall contact time due to displacement of the venous blood and an increased surface area of microbubbles (30). This results in a lower dosage and concentration requirement of sclerosant. When coupled with image guided injection, inadvertent arterial injection and ingress of sclerosant into deep veins can be avoided. This has reduced some of the complications that beset early trials of sclerotherapy as the

main treatment of varicose veins. Results from this technique are variable. Cavezzi (31) reported a 67% incidence of 'good' clinical outcome at a 2nd follow up appointment at between 6 weeks and 13 months, in contrast to a 91% incidence of 'good' outcome at an initial 30 day follow up. These are somewhat worse figures than Cabrera's reports of 81% LSV obliteration 3 years after microfoam sclerotherapy (32). In a refinement to this technique, (COMPASS – Comprehensive Objective Mapping, Precise image guided injection, Anti-reflux positioning and Sequential Sclerotherapy) whereby 3-monthly follow up visits for 1 year and planned re-injection of residual varicosities are written into the treatment protocol, success rates are again much better (33). McDonagh describes a recurrence rate of 1.7% after a mean follow up of 3.4 years using this regimen.

**Saphenofemoral valvuloplasty:** In a selected group of patients who have saphenofemoral incompetence with mobile valve leaflets of uniform length at the terminal saphenous valve, the LSV may be left in situ. Under local anaesthesia, the SFJ is exposed and a prosthetic external valve support in the form of a cuff of ePTFE or a specifically marketed device called the Venocuff (Vaso Inc, USA) is placed around the LSV at the site of the incompetent valve. This returns the SFJ to a competent junction and abolishes venous reflux and hence varicosities. It is a well-tolerated day case procedure with few complications. Unfortunately a majority of patients seem not to be suitable for such a procedure; only 64/421 (15%) in one series (34) were eligible for external banded valvuloplasty. In those that underwent this treatment there was a 12% recurrence rate at a mean of 52 months follow up. Importantly, there were no cases of periprosthetic infection. Yamaki *et al* (35) have recently described the addition of transposition of a competent tributary vein in addition to valvuloplasty and reduced their recurrence rates from 17.2% to zero at one years follow up.

**Conservative Haemodynamic cure of Incompetent and Varicose Veins in Ambulatory patients (CHIVA):** This method was first described by Claude Francheschi in 1983 (36) and spares the LSV by disconnecting the sites of venous reflux via stab incisions. It requires detailed preoperative Doppler assessment and identification of the types and sites of reflux including the entry and re-entry points of the venous shunts. Francheschi described 4 patterns of reflux and principles of treatment for each. Skin marking of these sites of reflux guides the placement of the skin incisions. It is an ambulatory procedure under local anaesthetic and is well tolerated

by the patients. Recurrence rates vary according to type of shunt present but in one series varied between 8-16% at mean follow up of 4 years (34). Maeso (37) compared CHIVA against LSV stripping in their department and showed at three year review that CHIVA had a significantly lower rate of recurrence (1% v 15%) on clinical assessment. They also reported a significantly lower incidence of saphenous nerve damage with CHIVA (1% v 19%) although they did not say how far the LSV had been stripped. Other studies, some from the French literature offer conflicting results. Gorny *et al* (38) suggested fewer recurrences after high ligation rather than CHIVA and Capelli's most recent paper on the subject described the rate of 'new visible vessels' as 22% at 3 years post-CHIVA (39). The concepts of CHIVA and haemodynamic surgery have not received widespread acceptance and are practised in only a few specialist centres in Europe.

**Subfascial Endoscopic Perforator Surgery (SEPS):** Open surgical division of the venous perforators of the medial calf as a treatment for the sequelae of chronic venous insufficiency such as venous ulceration has fallen out of favour because of the difficulties in healing a long wound in chronically diseased skin. Since initial reports of an endoscopic technique for perforator division in 1985 (40) many studies have detailed its feasibility and safety (41,42). The literature however, lacks well-powered randomised controlled studies of SEPS in the treatment of chronic ulceration. The case series that have been published however, do show impressive results in this rather depressing area of vascular therapy. Baron *et al* (43) healed 33 out of 37 active ulcers within 9 weeks after SEPS in their series with no recurrences at a mean of 44 weeks follow up. Similar results were obtained by Iafrati and colleagues (44) who report a 74% healing rate of severe chronic venous ulceration within 6 months. It should be noted that in many of these series, SEPS was undertaken in conjunction with surgical treatment of the saphenous veins and with postoperative layered compression. Venous ulceration is a notoriously recalcitrant condition and so long term follow up is vital to establish whether SEPS has a role to play in the treatment of chronic venous insufficiency.

**Transilluminated Powered Phlebectomy:** This is a patented (TriVex™ System, Smith + Nephew Inc, MA, USA) technology to minimise the number of stab incisions needed to complete avulsion of residual veins after treatment of the LSV and to ensure complete vein removal. A combined illuminator and hydrodissection instrument is inserted through a stab incision and a solution of dilute lignocaine infused under

pressure, effectively skeletonising the varicosities from the surrounding soft tissues. Insertion of the resection instrument through a second stab wound allows the displayed veins to be avulsed and aspirated away (45). Initial small-scale studies report good results in terms of patient satisfaction and minimal pain scores in the post-operative period (46) but as yet there are no comparative trials of the TriVex™ System against standard hook phlebectomy.

### Varicose veins in the military

Many of these techniques would appear to have distinct advantages for a service population. Foremost amongst the priorities of the military surgeon is the preservation of the fighting force; therefore, a method with reliable ablation of varicosities, rapid return to work, minimal incidence of complications and perhaps less importantly, preservation of a patent LSV would seem ideal. The only study examining the treatment of varicose veins in service personnel comes from the USA and actually examined none of these novel treatments. Brethauer *et al* (47) compared sclerotherapy with ambulatory phlebectomy after saphenofemoral and point perforator ligation. Uniquely in the literature pertaining to varicose veins, but perhaps not surprisingly, she reported a study population bearing more men than women. Ambulatory phlebectomy appeared to be the superior option with 75% of soldiers returning to full duties within 3 days of surgery. Recurrence rates between phlebectomy and sclerotherapy were virtually identical (11 & 12% respectively) at mean follow up of just over 1 year.

### Limitations of these new treatments

Many of these techniques have reported excellent results and would appear, superficially at least, to out-perform the current gold standard, but the mainstream surgical community has been slow to accept them. There are a number of reasons for this. Recurrence rates at 5-10 years after surgery are considered a reasonable marker of efficacy. None of these emerging treatments can provide comparable follow up and thus are viewed with scepticism. There is an important cost implication for some of these treatment methods in terms of longer operation times, expensive equipment purchase costs and the use of an ultrasonographer – essential in most techniques for guiding therapy. Although Rautio (21) demonstrated the VNUS Closure system could be cost effective in certain circumstances by including the reduction in indirect costs by a speedier return to work, it is questionable whether NHS trusts are sufficiently altruistic to meet the increased capital costs for the benefit of the community. Even the most

fervent supporter of endovenous treatments will concede that open operation is not finished yet; at least 30% of LSV varicosities are unsuitable for VNUS Closure due to the tortuous nature of the veins preventing passage of the catheter (19). A similar problem affects the EVLT equipment but to a slightly lesser degree due to the thinner laser catheter (26) and less than 15% of cases are suitable for external valvuloplasty (34). This may have implications for the training of surgeons in the future if the standard treatment for varicosities becomes endoluminal. New treatments may of course have new complications, and it is important to remember the incidence of skin burns when assessing these thermal ablation techniques – the incidence of dermal burns with standard surgery is zero. None of these methods has detailed any experience of treating short saphenous varicosities or saphenopopliteal incompetence.

Surgical dogma emphasises that complete clearance of all the tributaries at the SFJ must be cleared to ensure minimal rates of recurrence (48). None of these new methodologies deals with the tributaries at all. It is interesting to consider whether this represents erroneous dogma from decades of surgical studies or a true difference in the effects of treatment that may in time represent the most powerful argument of them all for the adoption of these new therapies. It has been suggested that by avoiding surgery in the groin there is no stimulus for angiogenesis and so neovascularisation is avoided. Alternatively, short-term follow up may be presenting a rose-tinted view of the results that time may well revise.

### Summary

There are many new methods to treat varicose veins being tried and tested around the world, many using patented techniques. They would appear to demonstrate many of the features a military surgeon might deem beneficial for treating a service population, a rapid return to duties amongst them. There are some significant drawbacks. All of these modalities need to offer long-term evidence of efficacy to demonstrate advantage over current standard. The endovenous therapies utilise expensive equipment that limit their introduction and provide a potential for novel complications as well as novel therapy. Modified sclerotherapy as described here has many advantages; it is incredibly cheap, minimally invasive and easily repeatable – in fact planned re-intervention is used in some protocols. Until long-term results are available, it would seem premature to recommend any of these new treatments for use in service personnel with primary varicose veins. Military vascular surgeons will await these results with interest, as the service population would have much to gain

from a modality that reliably treats the veins and ensures a swift return to service.

### References

1. Department of Health & Social Security. Hospital episodes statistics 1991/2. London: DHSS 1992.
2. Darke SG. The morphology of recurrent varicose veins. *Eur J Vasc Endovasc Surg* 1992; **6**: 512-7.
3. Corrales NE, Irvine A, McGuinness CL, Dourado R, Burnand KG. Incidence and pattern of long saphenous vein duplication and its possible implications for recurrence after varicose vein surgery. *Br J Surg* 2002; **89**(3): 323-6.
4. Hollingsworth SJ, Tang CB, Barker SGE. Primary varicose veins in the presence of an intact saphenofemoral junction. *Phlebology* 2001; **16**(2):68-72.
5. Labropoulos N, Giannoukas AD, Delis K *et al.* Where does venous reflux start? *J Vasc Surg* 1997; **26**(5): 736-42.
6. Ono T, Bergan JJ, Schmid-Schonbein GW, Takase S. Monocyte infiltration into venous valves. *J Vasc Surg* 1998; **27**(1): 158-66.
7. Waksman Y, Mashiah A, Hod I, Rose SS, Friedman A. Collagen subtypes in normal and varicose saphenous veins in humans. *Isr J Med Sci* 1997; **33**(2): 81-6.
8. Gillespie DL, Patel A, Fileta B *et al.* Varicose veins possess greater quantities of MMP-1 than normal varicose veins and demonstrate regional variation in MMP-1 and MMP-13. *J Surg Res* 2002; **106**(2): 233-8.
9. Ascher E, Jacob T, Hingorani A *et al.* Programmed cell death (apoptosis) and its role in the pathogenesis of lower extremity varicose veins. *Ann Vasc Surg* 2000; **14**(1): 24-30.
10. Hollingsworth SJ, Tang CB, Barker SGE. The effects of heparin on cultured explants of varicose long saphenous vein. *Phlebology* 2001; **16**(2): 60-67.
11. Cornu-Thenard A, Boivin P, Baud JM, De Vincenzi I, Carpentier PH. Importance of the familial factor in varicose disease. Clinical study of 134 families. *J Dermatol Surg Oncol* 1994; **20**(5): 318-26.
12. Burnand KG, Pattison M, Powell S, Lea Thomas M, Browse NL. Can we diagnose long saphenous vein incompetence correctly? In: Negus D, Jantet G, eds. *Phlebology*. London: John Libbey, 1985: 101-4.
13. McIrvine AJ, Corbett CR, Aston NO, Sherriff EA, Wiseman KG, Jamieson CW. The demonstration of saphenofemoral incompetence; Doppler ultrasound compared with standard clinical tests. *Br J Surg* 1984; **71**: 509-10.
14. Salaman RA, Fligelstone LJ, Wright IA, Pugh N, Harding KG, Lane IF. Hand-held bi-directional Doppler versus colour duplex scanning in the pre-operative assessment of varicose veins. *J Vasc Inv* 1995; **1**:183-6.
15. Mercer KG, Scott DJA, Berridge DC. Preoperative duplex imaging is required before all operations for primary varicose veins. *Br J Surg* 1998; **85**:1495-7.
16. Bradley L. Venous haemodynamics and the effects of compression stockings. *Br J Community Nurs* 2001; **6**(4): 165-75.
17. Dwerryhouse S, Davies B, Harradine K, Earnshaw JJ. Stripping the long saphenous vein reduces the rate of re-operation for recurrent varicose veins: five year results of a randomized trial. *J Vasc Surg* 1999; **29**(4): 589-92.
18. Taylor LM, Edwards JM, Porter JM. Present status of reversed vein bypass grafting: five year results in a modern series. *J Vasc Surg* 1990; **11**:193-206.
19. Fassiadis N, Kianifard B, Holdstock JM, Whitely MS. A novel endoluminal technique for varicose vein management: the VNUS closure. *Phlebology* 2002; **16**(4): 145-8.
20. Goldman MP, Amiry S. Closure of the greater saphenous vein with endoluminal radiofrequency thermal heating of the vein wall in combination with ambulatory phlebectomy: 50 patients with more than 6 month follow up. *Dermatol Surg* 2002; **28**(1): 29-31.

21. Rautio T, Ohinmaa A, Perälä J *et al.* Endovenous obliteration versus conventional stripping operation in the treatment of primary varicose veins: a randomized controlled trial with comparison of costs. *J Vasc Surg* 2002; **35**(5): 958-65
22. Merchant RF, DePalma RG, Kabnick LS. Endovascular obliteration of saphenous reflux: a multicenter study. *J Vasc Surg* 2002; **35**(6): 1190-6.
23. Fassiadis N, Kianifard B, Holdstock JM, Whitely MS. A novel approach to the treatment of recurrent varicose veins. *Int Angiol* 2002; **21**(3): 275-6.
24. Hayden A, Holdsworth J. Complications following re-exploration of the groin for recurrent varicose veins. *Ann R Coll Surg Engl* 2001; **83**: 272-3.
25. Proebstle TM, Lehr HA, Kargl A *et al.* Endovenous treatment of the greater saphenous vein with a 940-nm diode laser: thrombotic occlusion after endoluminal thermal damage by laser-generated steam bubbles. *J Vasc Surg* 2002; **35**(4): 729-36.
26. Min RJ, Zimmet SE, Isaacs MN, Forrestal MD. Endovenous laser treatment of the incompetent greater saphenous vein. *J Vasc Interv Radiol* 2001; **12**(10): 1167-71.
27. Einarsson E, Eklöf B, Neglen P. Sclerotherapy or surgery as treatment of varicose veins: a prospective randomized study. *Phlebology* 1993; **8**: 22-6.
28. Bergan JJ, Weiss RA, Goldman MP. Extensive tissue necrosis following high-concentration sclerotherapy for varicose veins. *Dermatol Surg* 2000; **26**(6): 535-41.
29. Min RJ, Navarro L. Trans catheter duplex ultrasound guided sclerotherapy for treatment of greater saphenous vein reflux: preliminary report. *Dermatol Surg* 2000; **26**(5): 410-14.
30. Di Stefano R, Frullini A, de Sanctis M, Mosca F. An endothelial model to test sclerosing agents in vitro. *Vasomed* 1999; Suppl 1: 7.
31. Cavezzi A, Frullini A, Ricci S, Tessari L. The treatment of varicose veins by foam sclerotherapy: two clinical series. *Phlebology* 2002; **17**(1): 13-18.
32. Cabrera J, Cabrera Jr. J, Garcia-Olmedo MaA. Treatment of varicose long saphenous veins with sclerosant in microfoam form: long-term outcomes. *Phlebology* 2000; **15**(1): 19-23.
33. McDonagh B, Huntley DE, Rosenfield R, *et al.* Efficacy of the Comprehensive Objective Mapping, Precise image guided injection, Anti-reflux positioning and Sequential Sclerotherapy (COMPASS) technique in the management of greater saphenous varicosities with saphenofemoral incompetence. *Phlebology* 2002; **17**(1): 19-28.
34. Zamboni P, Marcellino MG, Cappelli M *et al.* Saphenous vein sparing surgery: principles techniques and results. *J Cardiovasc Surg (Torino)* 1998; **39**(2): 151-62.
35. Yamaki T, Nozaki M, Sasaki K. Preliminary report of a new approach to sparing the greater saphenous vein for grafting: valvuloplasty combined with axial transplantation of a competent tributary vein. *J Endovasc Ther* 2001; **8**(2): 188-96.
36. Francheschi C. Théorie et pratique de la cure conservatrice de l'insuffisance veineuse en ambulatoire. Précy-sous-thil: Editions de l'Armançon, 1988 as quoted in Criado E, Luján S, Izquierdo L *et al.* Conservative hemodynamic surgery for varicose veins. *Semin Vasc Surg* 2002; **15**(1): 27-33.
37. Maeso J, Juan J, Escribano J *et al.* Comparison of clinical outcome of stripping and CHIVA for treatment of varicose veins in the lower extremities. *Ann Vasc Surg* 2001; **15**(6): 661-5.
38. Gorny PH, Blanchemaison D, Chahine B *et al.* Étude comparative entre CHIVA et crosssectomie chez 321 patients opérés de la saphène interne. Discussion. *Phléé* 1995; **48**: 255-9 as quoted in Criado E, Luján S, Izquierdo L *et al.* Conservative hemodynamic surgery for varicose veins. *Semin Vasc Surg* 2002; **15**(1): 27-33.
39. Capelli M, Molino Lova R, Ermini S *et al.* Ambulatory conservative hemodynamic management of varicose veins: critical analysis of results at 3 years. *Ann Vasc Surg* 2000; **14**: 376-84.
40. Hauer G. Die endoscopische subfasciale diszision der perforansvene-vorlaufige mitteilung. *VASA* 1985; **14**: 59.
41. Głowiczki P, Bergan JJ, Menawat SS *et al.* Safety, feasibility, and early efficacy of subfascial endoscopic perforator surgery: a preliminary report from the North American Registry. *J Vasc Surg* 1997; **25**: 94-105.
42. Stuart WP, Adam DJ, Bradbury AW, Ruckley CV. Subfascial endoscopic perforator surgery is associated with significantly less morbidity and shorter hospital stay than open operation (Linton's procedure). *Br J Surg* 1997; **84**: 1364-5.
43. Baron HC, Saber AA, Wayne M. Endoscopic subfascial surgery for incompetent perforator veins in patients with active venous ulceration. *Surg Endosc* 2001; **15**(1): 38-40.
44. Iafrafi MD, Pare GJ, O'Donnell TF, Estes G. Is the nihilistic approach to surgical reduction of superficial and perforator vein incompetence for venous ulcer justified? *J Vasc Surg* 2002; **36**(6): 1167-74.
45. Arumugasamy M, McGreal G, O'Connor *et al.* The technique of transilluminated powered phlebectomy – a novel, minimally invasive system for varicose vein surgery. *Eur J Vasc Endovasc Surg* 2002; **23**(2): 180-2.
46. Scavee V, Theys S, Schoevaerdts JC. Transilluminated powered miniphlebectomy: early clinical experience. *Acta Chir Belg* 2001; **101**(5): 247-9.
47. Brethauer SA, Murray JD, Hatter DG *et al.* Treatment of varicose veins: proximal saphenofemoral ligation comparing adjunctive varicose phlebectomy with sclerotherapy at a military medical center. *Vasc Surg* 2001; **35**(1): 51-8.
48. Sarin S, Scurr JH, Coleridge-Smith PD. Assessment of stripping the long saphenous vein in the treatment of primary varicose veins. *Br J Surg* 1992; **79**: 889-93.