

## CASE REPORT

### Cutaneous Myiasis Due To The Tumbu Fly During Operation Keeling

D Parkhouse

#### ABSTRACT

**Cutaneous myiasis is a temporary infestation of the skin with fly larvae (1). The following is a description of a case of cutaneous myiasis caused by the African Tumbu fly (*Cordylobia anthropophaga*). The clinical presentation and treatment of this infestation is discussed. A review of the Tumbu fly's lifecycle with emphasis on the prevention of the disease in the operational environment is also described.**

#### Introduction

In February 2003 the Spearhead Lead Element (SLE) deployed to Sierra Leone on Operation Keeling (OP Keeling). As with all deployments to tropical areas great importance was placed on force protection against tropical disease. Emphasis was placed on the prevention of malaria with the issue of mosquito nets and the impregnating of uniforms with Permethrin and strict dress regulations after dusk.

This case highlights the need for detailed history and understanding of parasitic life cycles to prevent erroneous diagnosis and a delay in appropriate treatment. It also highlights the need for environmental health awareness when contracts concerning locally employed civilians (LECs) are being drawn up.

#### Case presentation

A 30 year old male soldier while serving in Sierra Leone on OP Keeling reported sick complaining of an "itching boil" in his left groin. He had first noticed the boil three days previously. At that time he felt it was just a spot, the itching had only occurred in the last 24 hours. Previous to this he had been fit and well and had deployed to Sierra Leone ten days previously with the main body of SLE troops.

For the first six days he had been billeted in the Freetown peninsular in a house with running water and good sanitation, since then he had deployed with his unit to a company location outside of the Freetown area living and working in tented accommodation. Standard force protection in regards to tropical disease and prophylaxis had apparently been maintained including the use of insecticides, mosquito nets and the wearing of sleeves rolled down after dusk.

On examination the only thing of note was a small erythematous papule in the soldier's left groin area just inferior to the inguinal ligament. The lesion was approximately five millimetres in diameter. There was no obvious lymphadenopathy and no cellulitis. Conservative treatment was considered appropriate. The soldier was reassured and given advice about keeping the area as clean and dry as possible and told to return if the lesion worsened or did not spontaneously resolve in the next few days.

Four days later the soldier again reported sick. While washing he had squeezed the boil and in doing so a "maggot" had emerged from the boil (Figure 1). This had worried him enough to report sick immediately. On




Fig 1. The larva as it was recovered from the wound. A stage three larva.

examination the boil in the soldier's groin had been de-roofed revealing a cavity several millimetres in diameter with raised, thickened walls. The cavity itself appeared to be clean and empty. The "maggot" was pale in colour, five millimetres in length with two dark spots on its inferior aspect (Figure 2).

On further questioning concerning force protection and prevention of tropical disease the soldier explained that while billeted in Freetown his clothes were cleaned by LECs according to locally agreed contracts. When it came to the cleaning of tropical uniforms these were washed by hand and hung up to dry, the uniforms were not ironed before being returned to the soldiers.

Based on the presentation and the history

Lt Col D Parkhouse  
MBBS BSc FRCA  
RAMC

Consultant Anaesthetist  
16 Close Support  
Medical Regiment,  
16 Air Assault Brigade,  
Goojerat Barracks,  
Colchester

E Mail: hdp02@ukonline.co.uk

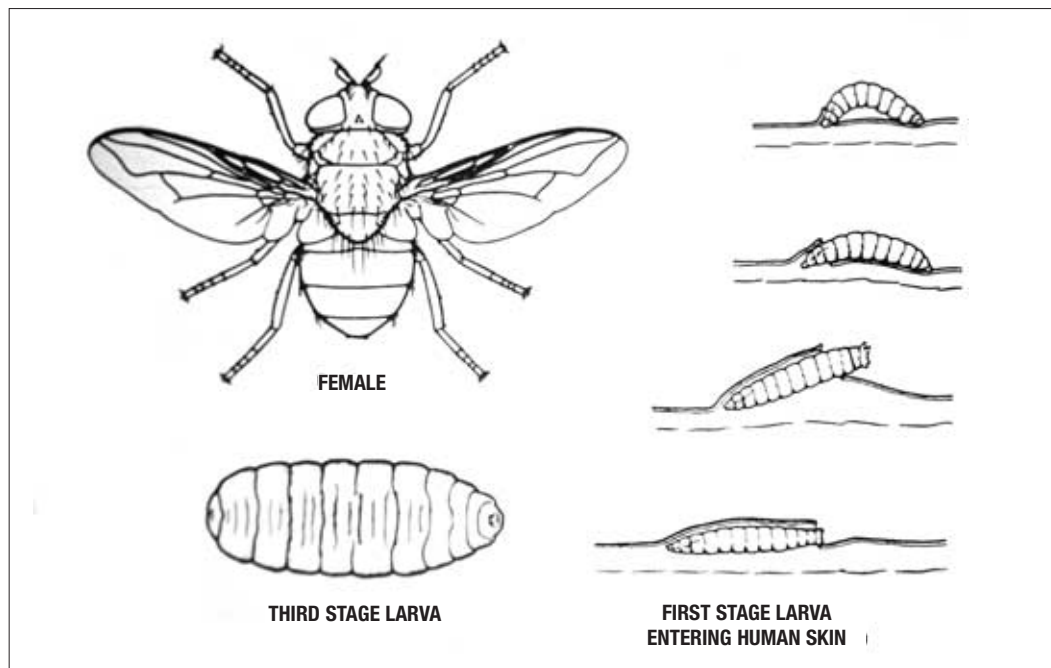


Fig 2. Depicts a female Tumbu fly, a stage one larva burrowing into skin and a stage three larva after leaving the host. Stage two (not shown here) corresponds to the time spent inside the host.

a diagnosis of cutaneous myiasis due to Tumbu fly larva was made. The larvae was not able to be formally identified by an entomologist.

The lesion in the soldier's groin was washed with antiseptic and the soldier placed on a course of broad spectrum antibiotics (co-amoxiclav 250/125 one tablet eight hourly for five days).

After this time the wound was reviewed and found to have healed leaving a small granulomatous lump less than two millimetres in diameter. The soldier was reassured and told to report to his medical centre on his return to the United Kingdom should he experience any problems with the lesion in the future.

A review of laundry practices was initiated to make sure that where possible, all laundry was ironed by the LECs before uniforms were returned to the soldiers.

## Discussion

Myiasis is the invasion of the tissues of man by any stage, usually the larvae, of athericerous flies (one suborder of flies out of three types) (2). It can be subdivided into three kinds:

1. Specific Myiasis, when the larvae develop only in (or in the case of the Congo Floor-maggot, *Auchmeromyia*, on) living flesh. Examples are *Chrysomya* or the Old World Screw-Worm fly (India), the *Cordylobia anthropophaga* or Tumbu fly (Africa) and the *Dermatobia hominis* or Human-Bot fly (Central America).
2. Semi-Specific Myiasis, when the larvae invade human wounds or sores, though normally breeding in carrion. Examples being the *Cochliomyia macellaria* or Green Bottle (America) or the *Lucilia*

*sericata* or Black Bottle (China).

3. Accidental Myiasis, when any or all stages of the fly may be found in, or passed, from the human alimentary tract or uro-genital organs. This type of myiasis is usually acquired by ingesting eggs or larvae with food. It can lead to severe digestive tract disturbances and other symptoms. Examples are *Fanna canicularis* or Lesser House fly and the *Megaselia scalaris* or Phorid flies.

The Tumbu Fly is well known in the tropical Ethiopian and West African regions (3). Its life cycle starts with the female fly laying up to 500 eggs on damp vegetation, soil or clothes usually contaminated with urine or perspiration. The eggs hatch within 24 hours to three days. The first stage larvae are very sensitive to body heat quickly seizing onto and burrowing under the skin within a few minutes (Figure 2). In man the back, neck and scrotum are the most common places. After eight to ten days development in the tissues the mature larva, or the third stage larva, drops out of the host and hardens into a pupae stage for three weeks until the fly emerges.

Myiasis due to the larvae of the Tumbu fly (*Cordylobia anthropophaga*) typically produces a round erythematous papule a few millimetres in diameter. Within a few days the lesion becomes an inflamed nodule up to 2cm in diameter surrounded by an erythematous ring. At the top of the nodule there may be a small ulcer or depression; this corresponds to its respiratory apparatus (4).

A serous fluid can sometimes be witnessed exuding from the lesion, this corresponds to a mixture of the larvae faeces, inflammatory cells and necrotic tissue(5). The lesion is classically misdiagnosed as an infected hair

follicle or a furuncle, the lesion is often accompanied by intense pruritus or burning or the sensation of movement under the skin(6). The main sequelae associated with the Tumbu fly is the inflammatory response and secondary infection which can be particularly virulent should parts of the larva remain in the host due to incomplete removal(7). Treatment should involve extraction of the larva and antibiotic prophylaxis to prevent abscess formation.

Prevention must be based upon good sanitation and avoidance of infested areas (2), avoid sleeping on the ground and keeping rat and dog numbers low as these are the fly's natural hosts. All laundry should be ironed where possible as the heat generated will kill any eggs laid on the clothes.

### Summary

High quality Environmental Health care is extremely important in the prevention of tropical disease. This should start even before troops are deployed into the operational area with input into the contractual arrangements of LECs to maximise force protection from tropical disease and other non battle injury. The ironing of laundry in areas endemic with

Tumbu Fly should be considered a priority in the prevention of tropical disease. In circumstances where this is not possible prevention is dependant on avoidance of infested areas and in particular avoiding hanging laundry in infested areas. The effect of insecticides against these types of fly is unknown, as a result a high index of suspicion concerning skin lesions of this nature is required so as not to miss cases of Cutaneous Myiasis.

### References

1. James AS, Stevenson J. Cutaneous myiasis due to Tumbu fly. *Arch of Emerg Med* 1992; **9**(1):58-61.
2. Burgess NR. *Arthropods of medical importance*. London, Noble books Ltd, 1981.
3. Wildy GS, Glover SC. Myiasis due to Tumbu fly larva. *Lancet* 1982; **i**:1130-1.
4. Veraldi S, Gorani A, Schiani R. Non inflammatory cutaneous myiasis caused by the larva of *Cordylobia anthropophaga*. *Euro J Dermatol* 1998; **8**(2):133-4.
5. Vervaldi S, Brusasco A, Suss L. Cutaneous myiasis caused by larvae of *Cordylobia anthropophaga*. *Int J Dermatol* 1993; **32**:184-7.
6. Ockenhouse C, Samlaska C, Benson P. Cutaneous myiasis caused by the African Tumbu fly (*Cordylobia anthropophaga*). *Arc Dermatol* 1990; **126**(2):199-202.
7. Mitchell R. Tumbu fly. *BMJ* 1972; **2**(809):351.