

SELF ASSESSMENT

Self-Assessment Questions In The Management Of Major Trauma

JE Smith

You are working in the Emergency Department of a Military District Hospital Unit. The following patients present to your resuscitation room.

1. You are called to see a patient who has been involved in a motor vehicle collision. He was the restrained driver of a vehicle that crashed into a tree on a country road at approximately 70mph. He was walking at the scene but the ambulance crew have instituted spinal precautions on the basis of the mechanism of injury. His respiratory rate, pulse and BP are all within normal limits. Secondary survey reveals that he has a transverse linear contusion across his lower abdomen just below the level of the umbilicus (see Figure 1), and some lower abdominal tenderness to palpation.

- What are your priorities in management?
- What pattern of injury would you be particularly concerned about?
- How would you exclude this injury?

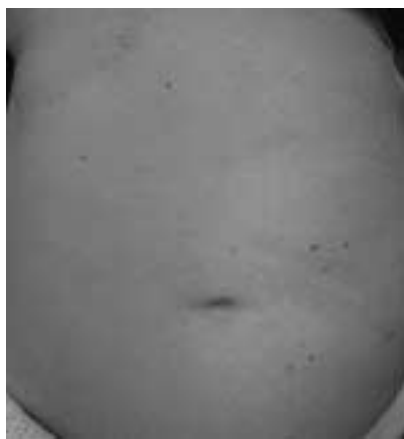

Fig 1. Linear contusion of lower abdomen.

2. You are involved in the resuscitation of a patient with multi-system injuries resulting from a motorbike accident. After the initial phase of resuscitation his core temperature is 35°C. Arterial blood gas analysis shows his pH is 7.22 with a base deficit of 12. By this stage he has had two litres of crystalloid, and is receiving his sixth unit of packed red cells.

- What is the *lethal triad* of trauma?
- What else should this patient receive?
- How can you prevent these complications?

3. A young male patient is brought in by ambulance having been stabbed in the abdomen. On examination he has a patent airway, is breathing spontaneously with a respiratory rate of 18 per minute, his pulse is 90bpm, and his BP is 110/80. On questioning he says he was just walking down the street and someone came up and stabbed him with a knife for no apparent reason.

Secondary survey reveals a wound consistent with a knife entry wound about 4cm long, just above and to the left of his umbilicus, with some local tenderness around the wound.

- What are your management priorities?
- What is the likelihood that he has sustained an injury to the diaphragm?
- What is the investigation strategy of choice in a haemodynamically stable patient with an anterior abdominal stab wound?
- How would this differ if he sustained a flank or back stab wound?

4. A 22-year-old man is brought in having been assaulted with an iron bar. The ambulance crew estimate that he had lost about 1 litre of blood at the scene from a scalp laceration. He has obvious head injuries, has a potentially compromised airway, is breathing with a respiratory rate of 25, has a pulse of 110bpm, and a systolic BP of 120mmHg. He is groaning, his eyes are closed, and he is localising to painful stimuli. He appears to be moving all four limbs.

- What are your priorities in management?
- How are you going to prevent further secondary brain injury?
- Should you give mannitol?
- Should you give steroids?

5. The restrained driver of a car that has been T-boned at 50mph is brought into the resuscitation room complaining of chest pain and shortness of breath. Her airway is patent, respiratory rate 30 per minute with equal air entry, pulse 100bpm, BP 110/90. She is alert and orientated. Her chest X-ray is shown at Figure 2.

Surg Lt Cdr J E Smith
MBBS MSc MRCP
FFAEM RN

Specialist Registrar in
Emergency Medicine,
Defence Medical
Services

Department of Trauma,
Liverpool Hospital,
Liverpool, NSW 1871,
Australia.

jasonsmith@doctors.org.uk

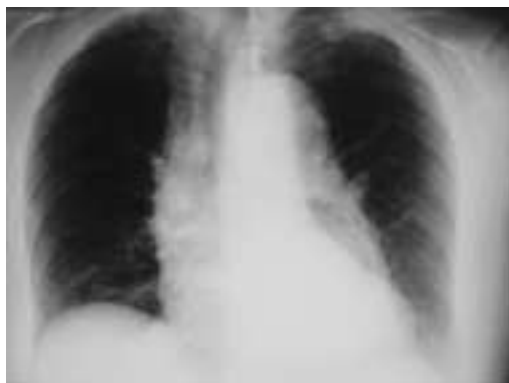

Fig 2. Chest X-ray.

- What are your priorities in management?
- What injury in particular are you concerned about?
- What is the investigation of choice to detect this?

Answers to self assessment questions.

Question 1.

- Primary and secondary surveys are complete. Adjuncts to these should also be performed – spinal precautions, high flow oxygen, intravenous access, primary survey radiology (chest and pelvis X-rays), urinary and gastric catheters. Further assessment of the abdomen with FAST (if available) and CT.
- Once other more life-threatening problems have been excluded the seat belt syndrome should be suspected – seat belt abrasion of the lower abdomen associated with hollow viscus injury.
- CT is not a sensitive test for hollow viscus injury, although it may show evidence such as thickening of the bowel wall or intraperitoneal gas. Management options include repeated clinical examination, diagnostic peritoneal lavage (DPL), laparoscopy or exploratory laparotomy.

Discussion

Trauma teaching rightly concentrates on detection of intra-abdominal haemorrhage as the primary concern when assessing abdominal injuries, but this is sometimes at the expense of suspicion of injury to a hollow viscus. Several mechanisms may contribute to intra-abdominal injury during motor vehicle crashes, including acceleration or deceleration shear stresses and compression of the abdominal contents by external forces such as a seatbelt. Damage to hollow organs can occur directly or as a result of increased pressure within the abdominal cavity (1).

The seatbelt syndrome was first described by Garrett and Braunstein in 1962 (2) and describes rapid deceleration and flexion of the upper torso around the lap portion of the seatbelt, producing compression of the

bowel against the spine. The classic sign is bruising over the lower abdomen corresponding to the position of the lap belt. It is associated with lumbar spine (Chance) fractures.

Hollow viscus injury is often difficult to

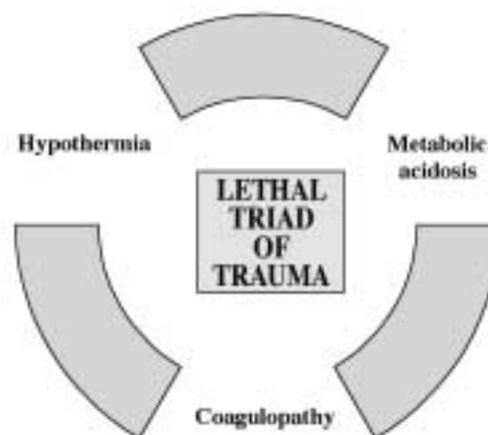


Fig 3. The lethal triad of trauma.

diagnose, and relies on the clinician suspecting that it may be present. Given an appropriate mechanism of injury, repeated clinical examination is the usual method of assessment, but this needs to be augmented by further investigation as necessary. Haemodynamically unstable patients require surgery, but in stable patients CT is often the next step. Abdominal CT scanning may show evidence of injury to the hollow viscus, with gas within the peritoneal cavity or thickening of affected bowel, but a normal CT does not rule out hollow viscus injury. In cases of doubt, admission for observation and repeated clinical examination is a sensible option. This could be one of the remaining uses of DPL in abdominal trauma. If the patient develops frank peritonism or evidence of intra-abdominal sepsis, they will need definitive surgery.

Question 2

- Hypothermia, acidosis and coagulopathy.
- Adequate resuscitation to optimise oxygenation and perfusion. Haemorrhage control. Active warming. Other blood products such as fresh frozen plasma, platelets and cryoprecipitate.
- By looking after A, B, C, D and E.

Discussion

The lethal triad is a term given to the combination of hypothermia, acidosis and coagulopathy, each of which contributes to the other (Figure 3). This can become apparent early in the management course of the trauma patient. The multiply injured patient is often in a state of oxygen debt as a result of hypoperfusion, made worse if hypothermia reduces the ability of haemoglobin to release oxygen to the tissues. This contributes to metabolic

derangement with metabolic (lactic) acidosis being the result. Hypothermia also contributes to a reduction in coagulation cascade enzyme activity with a significantly prolonged prothrombin time and activated partial thromboplastin time at temperatures $<35^{\circ}\text{C}$, with a concomitant reduction in platelet function (3). This is exacerbated by haemodilution that results from infusion of large quantities of crystalloid during resuscitation. Continued bleeding results in hypoperfusion and further heat loss, worsening the acidosis and hypothermia (4,5).

This cycle can best be prevented by keeping the trauma patient warm, optimising oxygenation and perfusion, stopping haemorrhage, and in the presence of coagulopathy replacement of platelets and clotting factors. Controlling E (environment) is of paramount importance and some trauma centres in the USA go as far as keeping their resuscitation rooms at body temperature to reduce the possibility of inducing hypothermia.

The concept of damage control surgery to facilitate this phase of resuscitation has become accepted standard of care, where control of haemorrhage and limitation of contamination are the priorities rather than prolonged definitive organ repair (6,7).

Question 3

- Primary and secondary surveys are complete but no radiology done yet. Needs chest X-ray. Priority is to rule out significant intra-abdominal or intra-thoracic injury.
- Risk of occult diaphragmatic injury in anterior stab wounds not requiring surgery for other reasons estimated at 7% (8).
- Options are repeated clinical examination, local wound exploration, diagnostic peritoneal lavage (DPL), laparoscopy or exploratory laparotomy. Protocol will depend on the local expertise and facilities available.
- There is a role for triple contrast computed tomography (CT) in risk-stratifying back and flank stab wounds.

Discussion

The management decisions involved in assessing patients with abdominal stab wounds are often made easier if there is haemodynamic instability, as this group of patients require surgery and haemorrhage control. However, in patients who are haemodynamically normal, with no signs of peritonism or evisceration, the dilemma is how to exclude significant injury while exposing the patient to minimal risk from invasive procedures; in the past most of these patients were subjected to exploratory laparotomies to look for intra-abdominal injury.

The first option is serial physical examination, which has had some success (9), although it is labour intensive and not usually practical in a busy hospital setting. It is unreliable if the patient is intoxicated, has a reduced conscious level, or is less than fully cooperative. Next is local wound exploration, to establish whether the anterior abdominal fascia has been breached (10). This procedure depends on the expertise of the operator, and in experienced hands can exclude the need for further investigation. If the fascia has been breached, further investigation is needed to further evaluate the extent of injury. This could be in the form of a DPL which, if positive, should prompt exploration at laparotomy (11). If negative, the patient can be observed. The exact algorithm for management of these patients needs to be agreed locally and will depend on the expertise and resources available. Cameron *et al.* have devised an example (12).

In thoracoabdominal wounds a diaphragmatic injury should be suspected and excluded by either laparoscopy or thoracoscopy. Stab wounds to the flank and back may injure structures within the retroperitoneum that will not be initially apparent on clinical examination. Triple contrast CT is useful to evaluate these structures and dictate the need for further intervention (13,14).

Question 4

- Assessment and treatment of ABCDE:
 - Airway – needs endotracheal intubation with cervical spine immobilisation
 - Breathing – check for evidence of life-threatening chest problems while giving high flow oxygen
 - Circulation – needs intravenous cannulation and administration of fluid to maintain reasonable mean arterial pressure, along with control of bleeding from scalp laceration
 - Disability – assess GCS (E1V2M5 = 8), pupils and gross peripheral neurology
 - Exposure and environment – fully expose to do full secondary survey and assess for other injuries, while controlling environment and preventing hypothermia
- Prevent the causes of secondary brain injury (see Table 1).
- Seek advice from local neurosurgical centre (see discussion).
- Not currently recommended. Awaiting results of CRASH trial.

Table 1. causes of secondary brain injury.

- | |
|--|
| <ul style="list-style-type: none"> Hypoxia Hypotension or hypertension Hypocarbica or hypercarbica Hypoglycaemia or hyperglycaemia Seizures |
|--|

Discussion

During the primary and secondary surveys, and following this phase of resuscitation, priorities in head injury management should be control of those factors that contribute to secondary brain injury. The only way to prevent primary insults are primary preventative measures such as legislation and education. Secondary brain injury, the causes of which are listed in Table 1, can be prevented by control of ventilation and cerebral perfusion, and prompt treatment of seizure activity.

The essence of this is maintenance of an adequate cerebral perfusion pressure (CPP), described by the equation -

$$\text{CPP} = \text{mean arterial pressure (MAP)} - \text{intracranial pressure (ICP)}.$$

CPP can, therefore, be maintained by manipulation of MAP (ensuring adequate blood pressure by intravenous fluids and the use of inotropes) and control of ICP, which can be reduced in several ways. Simple procedures such as nursing the patient 30 degrees head up and ensuring that a cervical collar is not obstructing venous return have been shown to effect ICP. To optimise oxygenation and ventilation it is often necessary to intubate and mechanically ventilate the patient to achieve a PaCO₂ at the low end of normal range. The idea that intracranial pressure can be reduced by hyperventilation (causing cerebral vasoconstriction, therefore, reducing the amount of intravascular blood within the cranium) neglected the fact that hypocarbia, in producing cerebral vasoconstriction, also reduces cerebral perfusion and, therefore, oxygenation. One study examining cellular mediators of injury in ventilated head injury patients found increased levels of these cytokines in patients who were hyperventilated, suggesting more cellular damage in patients when the PaCO₂ is lower than the normal range (15).

Mannitol is an osmotic diuretic used to reduce ICP by drawing fluid from the interstitial space into the intravascular compartment. It can be either used as a slow bolus, or as an infusion. A recent Cochrane review concluded that high dose mannitol is better than standard dose (1.4g/kg v 0.7g/kg), it may buy time pre-operatively for defined lesions that are amenable to neurosurgical drainage, but there is no evidence about infusion for patients with non-operable pathology (e.g. diffuse axonal injury) (16). In practice it should be given on the advice of the local neurosurgical referral unit.

The results of the Medical Research Council Corticosteroid Randomization after Significant Head injury (CRASH) trial

are eagerly awaited, but steroids are not currently recommended for these patients.

Question 5

- Primary and secondary survey, treat any co-existing life threatening conditions. If aortic injury is present control of blood pressure is mandatory prior to definitive repair.
- Aortic injury.
- Either CT angiography or arch aortogram, depending on local expertise.

Discussion

This particular mechanism of injury (lateral impact MVC) is associated with a high risk of traumatic aortic injury. This is due to the sudden lateral shear force applied to the mobile aortic arch in relation to the relatively immobile descending aorta (fixed by the ligamentum arteriosum), and results in most aortic injuries occurring at the proximal descending aorta (17,18). In one retrospective review half of patients with traumatic aortic rupture were the victims of lateral impact MVCs (19).

This injury results in a significant number of deaths following high energy trauma, a large proportion of which occur at the accident scene. Those who survive to be assessed in the Emergency Department usually have contained aortic haemorrhage from a partial thickness tear, and need to have rapid identification of other injuries and control of co-existing haemorrhage. The use of anti-hypertensive agents to control blood pressure lessens the risk of rupture prior to definitive repair (20).

The first sign that there may be aortic injury is usually an abnormal chest X-ray. Abnormalities suggesting aortic injury include widening of the mediastinum (>8cm at the level of the aortic arch), depression of the left mainstem bronchus, an apical pleural cap (haematoma), or abnormal deviation of the nasogastric tube.

Further investigation may include CT, arch aortogram, or both. The accepted gold standard investigation historically has been the aortogram, although newer CT technology has improved the sensitivity of this investigation to close to 100% (20,21), and this is often used as a screening test if facilities are available.

References

- Campbell DJ, Sprouse LR 2nd, Smith LA, Kelley JE, Carr MG. Injuries in pediatric patients with seatbelt contusions. *Am Surg* 2003; **69**(12): 1095-1099.
- Garrett JW, Braunstein PW. The seat belt syndrome. *J Trauma* 1962; **2**: 220-238.
- Reed RL 2nd, Bracey AW Jr, Hudson JD, Miller TA, Fischer RP. Hypothermia and blood coagulation: dissociation between enzyme activity and clotting factor levels. *Circ Shock* 1990; **32**(2): 141-52.

4. Eddy VA, Morris JA Jr, Cullinane DC. Hypothermia, coagulopathy, and acidosis. *Surg Clin North Am* 2000; **80(3)**: 845-54.
5. Tsuei BJ, Kearney PA. Hypothermia in the trauma patient. *Injury* 2004; **35(1)**: 7-15.
6. Moore EE, Thomas G. Orr Memorial Lecture. Staged laparotomy for the hypothermia, acidosis, and coagulopathy syndrome. *Am J Surg* 1996; **172(5)**: 405-10.
7. Guy RJ, Edwards PD, Fichtner KA. Surviving the lethal triad of trauma: a case from Kosovo. *J R Nav Med Serv* 2003; **89(2)**: 67-72.
8. Leppaniemi A, Haapiainen R. Occult diaphragmatic injuries caused by stab wounds. *J Trauma* 2003; **55(4)**: 646-50.
9. van Haarst EP, van Bezooijen BP, Coene PP, Luitse JS. The efficacy of serial physical examination in penetrating abdominal trauma. *Injury* 1999; **30(9)**: 599-604.
10. Taviloglu K, Gunay K, Ertekin C, Calis A, Turel O. Abdominal stab wounds: the role of selective management. *Eur J Surg* 1998; **164(1)**: 17-21.
11. Leppaniemi A, Haapiainen R. Diagnostic laparoscopy in abdominal stab wounds: a prospective, randomized study. *J Trauma* 2003; **55(4)**: 636-45.
12. Cameron P, Civil I. The management of anterior abdominal stab wounds in Australasia. *Aust N Z J Surg* 1998; **68(7)**: 510-3.
13. Boyle EM Jr, Maier RV, Salazar JD, *et al*. Diagnosis of injuries after stab wounds to the back and flank. *J Trauma* 1997; **42(2)**: 260-5.
14. Albrecht RM, Vigil A, Schermer CR, Demarest GB 3rd, Davis VH, Fry DE. Stab wounds to the back/flank in hemodynamically stable patients: evaluation using triple-contrast computed tomography. *Am Surg* 1999; **65(7)**: 683-7.
15. Marion DW, Puccio A, Wisniewski SR, *et al*. Effect of hyperventilation on extracellular concentrations of glutamate, lactate, pyruvate, and local cerebral blood flow in patients with severe traumatic brain injury. *Crit Care Med* 2002; **30**: 2619-2625.
16. Roberts I, Schierhout G, Wakai A. Mannitol for acute traumatic brain injury. Cochrane Injuries Group. *Cochrane Database of Systematic Reviews*. 1, 2004.
17. Williams JS, Graff JA, Uku JM, Steinig JP. Aortic injury in vehicular trauma. *Ann Thorac Surg* 1994; **57(3)**: 726-30.
18. Shkrum MJ, McClafferty KJ, Green RN, Nowak ES, Young JG. Mechanisms of aortic injury in fatalities occurring in motor vehicle collisions. *J Forensic Sci* 1999; **44(1)**: 44-5.
19. Katyal D, McLellan BA, Brennehan FD, Boulanger BR, Sharkey PW, Waddell JP. Lateral impact motor vehicle collisions: significant cause of blunt traumatic rupture of the thoracic aorta. *J Trauma* 1997; **42(5)**: 769-72.
20. Fabian TC, Davis KA, Gavant ML, *et al*. Prospective study of blunt aortic injury: helical CT is diagnostic and antihypertensive therapy reduces rupture. *Ann Surg* 1998; **227(5)**: 666-76.
21. Dyer DS, Moore EE, Ilke DN, *et al*. Thoracic aortic injury: how predictive is mechanism and is chest computed tomography a reliable screening tool? A prospective study of 1,561 patients. *J Trauma* 2000; **48(4)**: 673-82.