

# STEROID INJECTIONS IN FIELD HOSPITAL

## The Role of Local Steroid Injections in an Operational Field Hospital Setting

A Ramasamy, RR Shah, TPS Bhullar, F Warnock, T Pitman

### ABSTRACT

#### Objectives

To assess the safety and effectiveness of administering local steroid injections in an operational field hospital environment.

#### Method

A prospective study of patients presenting to the physiotherapy department at the British Military Hospital (BMH) Shaibah, Iraq was undertaken from July 2006 – September 2006. Patients with a condition amenable to local steroid injection and who had not improved with conservative therapy were considered for the study. They then underwent local injection with steroid and local anaesthetic.

#### Results

During this period 12 patients were identified that fitted the criteria for local steroid injection. This represented 7% (12/179) of patients who were seen by the physiotherapy department in either an in or out-patient setting. All patients were injected with local anaesthetic and steroid injection with a single dose of intravenous antibiotic as antimicrobial cover. 10/12 (83.3%) were able to return to their unit within this theatre of operation. The only complication was one case of post injection flare of pain, which settled after 48 hours.

#### Conclusion

The use of local steroid injection, as an adjunct to physical therapy, can enable service personnel to remain in the theatre of operations. These patients may have otherwise required aero medical evacuation. We consider the use of a local steroid injection to be a safe and effective intervention in certain patients where conservative measures alone do not work. This study highlights the safety of using steroid injections in an operational field hospital setting. Further large scale studies may help corroborate this conclusion.

### INTRODUCTION

Soft tissue and joint injections are widely used for the diagnosis and therapy of a variety of musculoskeletal conditions. The delivery of corticosteroids is used for the suppression of

inflammation. These injections are most useful in instances of joint or tissue injury and inflammation(1). There is evidence on the positive effects of corticosteroid administration in the treatment of subacromial bursitis(2), plantar fasciitis(3, 4), trochanteric bursitis(5), and acromioclavicular joint pathology(6).

These conditions can be extremely debilitating and would significantly reduce the ability of service personnel to function in an operational environment. The main concern about the use of steroid injection is the potential risk of infection, which can be potentially devastating. The risk of severe infection following local steroid injection is rare and has only been reported sporadically in medical literature<sup>(7,8)</sup>.

To date, there are no reports in the medical literature of the use of local steroid injections in an operational field setting. The aim of this study was to ascertain the safety of local steroid injection and to assess their effectiveness in keeping service personnel in this operational environment.

### METHOD

A prospective analysis of patients presenting to the physiotherapy department at BMH Shaibah, from July 2006 – September 2006 was undertaken. Only patients, who had failed to improve with conservative measures and had a condition amenable to local steroid injection, were included in the study. Where appropriate, the diagnosis was confirmed by radiological imaging and biochemical investigations. Any patient with a concomitant infective process was excluded from the study. All patients consented to having a steroid injection and the risks of infection, post injection flare of pain and recurrence of symptoms was discussed(9).

The procedure was undertaken under aseptic conditions in the operating theatre. A single dose of intravenous broad spectrum antibiotic (Cefuroxime 1.5 gm) was given just prior to the steroid injection. The skin was cleaned using alcohol Betadine solution. Sterile drapes were used to isolate the injection site. Sterile gloves were worn to administer the steroid injection. In addition, the needle was changed between drawing the steroid and giving the injection. All patients were injected with a steroid (Methylprednisolone acetate 40-80mg, Depo-Medrone<sup>®</sup>) combined with a local anaesthetic (Anhydrous bupivacaine hydrochloride 0.5%, Marcain<sup>®</sup> 0.5%).

Maj A Ramasamy MA  
MRCS(Glas), Surgical  
SHO. \*(corresponding  
author)

Surg Cdr RR Shah  
FRCS (Tr and Orth),  
Consultant Orthopaedic  
Surgeon.

Wg Cdr TPS Bhullar  
FRCS FRCS (Ed  
Orth), Consultant  
Orthopaedic Surgeon.

Capt F Warnock BSc  
(Hons), MCSP,  
Physiotherapist.

Capt T Pitman BSc  
(Hons), MCSP,  
Physiotherapist.

BMH Shaibah, Op  
TELIC 8, Iraq, BFPO  
645.

Corresponding Author:  
Maj Arul Ramasamy,  
RAMC  
3 Broad Garth, Quayside,  
Newcastle Upon Tyne  
NE1 3HE  
Tel: 0191 2611511/  
07968 147007  
Email: arul49@doctors.org.uk

Following injection, a sterile adhesive dressing was applied to the injection site. Patients were then observed on the ward for 24 hours post procedure. After discharge from the ward, the patients were followed up by the physiotherapy department. Any cases that were subsequently aeromedically evacuated or re-referred to the orthopaedic department were deemed to be a failure of treatment.

## RESULTS

During the study period, 172 patients were treated in the physiotherapy department. 12 patients (7%) were considered suitable for inclusion in the study. 3 (25%) had acute injuries and 9 (75%) had chronic conditions. The median duration of symptoms prior to injection was 14.5 weeks (Range 1-104, mean 27.5).

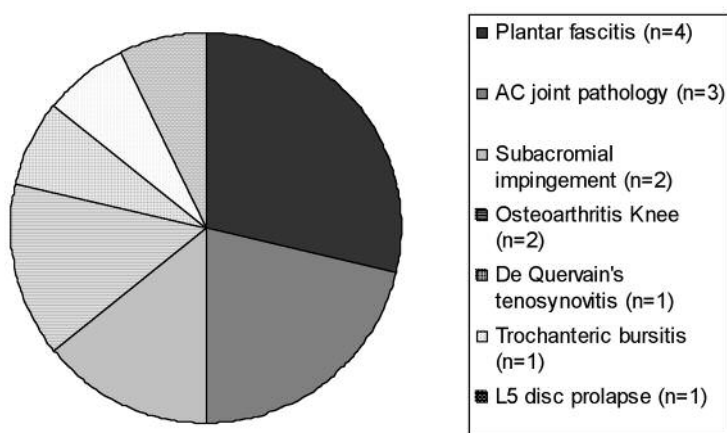


Figure 1. Conditions treated by steroid injection.

The patients were treated for a variety of pathologies that are represented in Figure 1. There were 2 cases of osteoarthritis (OA) of the knee that were included in the study. Both had symptomatic effusions of the joint, which was initially aspirated. Unfortunately the effusions returned shortly after and the decision was taken to undertake a second aspiration of the joint followed by steroid injection. The 3 patients who suffered an acute onset of symptoms, presented with significant symptoms that had failed to respond to intensive daily inpatient physiotherapy. These patients would have required aeromedical evacuation if they had not responded to the steroid injection.

In total, 19 injections were administered and 2 patients (16%) underwent 2 courses of steroid injections. The result of the injections is found in Table 1. All patients were reviewed in the physiotherapy department after the procedure (mean 5.48 weeks, range 1.7-11.4 weeks). Following injection, 10 patients (83.3%) were returned to their unit in theatre. After discharge from the physiotherapy department, none of these patients were subsequently re-referred to the orthopaedic department for worsening symptoms and

none were aeromedically evacuated for their condition. Of the 2 (16.7%) that required aeromedical evacuation, the first patient had temporary relief of symptoms following the injection but his symptoms returned after he failed to comply with the rehabilitation program. The second patient was admitted with severe discogenic pain and the epidural was a temporising measure designed to reduce his symptoms prior to his aeromedical evacuation.

In terms of complications, only 1 patient (8.3%) had a post-steroid flare of pain, which required an extra night stay in hospital. His symptoms were self-limiting and resolved within 48 hours. He was then returned to his unit. There were no reported cases of long-term complications during the study period.

## DISCUSSION

Corticosteroids suppress inflammation and decrease erythema, swelling and tenderness around the affected site. These effects are mediated through a variety of mechanisms, including alterations in neutrophil chemotaxis and function, increases in viscosity of synovial fluid, stabilisation of cellular lysosomal membranes, alterations in hyaluronic synthesis, transient decreases in synovial fluid complements, alterations in synovial permeability and changes in synovial fluid leukocyte count and activity(10).

A number of potential complications can arise from the administration of local steroid injection. Local infection is of the greatest concern and can potentially lead to sepsis. However cases of severe infection following steroid injection are extremely rare and have only been described sporadically in the medical literature(7,8). In a survey of orthopaedic consultants in the UK and Ireland (n=759), only 68 cases of infection could be recalled. In the same survey, almost half of the surgeons polled perceived the risk of infection was 1:1000 whilst a third of surgeons believed it to be 1:10000(11). There is also a wide variation in the antiseptic precautions taken during intra-articular steroid injection. A questionnaire posted to orthopaedic surgeons, rheumatologists and general practitioners revealed only 16.3% used sterile towels to isolate the injection site and 32% used sterile gloves when injecting. Despite this variation of technique there was no change in the incidence of infection (12).

Our method of administering local steroid injection was aimed at reducing the potential risk of infection from the treatment. The use of intravenous antimicrobial cover prior to injection is not routinely used in normal civilian practice. A recent study from an US military hospital in Baghdad revealed a high proportion of

Patient No.	Condition	Acute/ Chronic	Duration of symptoms	Total No. of injections	Site of injection (number of courses)	Complications	Outcome
1	Subacromial	Acute	1	4	Subacromial (2)	Nil	RTU
2	OA knee	Chronic	104	1	Knee (1)	Nil	RTU
3	Plantar fasciitis	Chronic	12	2	Plantar fascia (2)	Nil	Aeromed
4	De Quervains tenosynovitis	Chronic	12	1	Thumb (1)	Nil	RTU
5	Trochanteric Bursitis	Chronic	16	1	Trochanteric Bursa (1)	Post-steroid flare of pain.	RTU
6	Subacromial	Acute	2	2	Subacromial (1)	Nil	RTU
7	Plantar fasciitis	Chronic	16	1	Plantar fascia (1)	Nil	RTU
8	Plantar fasciitis	Chronic	13	1	Plantar fascia (1)	Nil	RTU
9	AC Joint	Chronic	78	1	AC Joint (1)	Nil	RTU
10	Plantar fasciitis	Chronic	17	1	Plantar fascia (1)	Nil	RTU
11	L5 Disc	Acute	8	3	Caudal epidural and bilateral L5 root block (1)	Nil	Aeromed
12	OA Knee	Chronic	52	1	Knee (1)	Nil	RTU

Table 1. Results of local steroid injections.

coagulase negative staphylococcus (34%), *S. Aureus* (26%) and *Streptococci* species (11%) in microbiological samples taken from US personnel treated at that facility. They also found positive cultures of *Acinetobacter baumannii* ten times more prevalent in the deployed hospital compared to military hospitals in USA(13). In view of the potential increase risk of infection and the possibility that patients may deploy to remote areas shortly after the procedure, we felt it was prudent to administer a single dose of a broad-spectrum cephalosporin intravenously prior to injection.

Apart from infection, other complications include post-injection steroid flare. This is thought to be a crystal-induced synovitis caused by preservatives in the injectable suspension. This usually occurs within the first 24 hours after injection and is a self-limiting condition(14). Fat atrophy and local depigmentation are late complications and peri-articular calcification has also been described in the literature.

## CONCLUSION

Our data suggests that local steroid injections can be administered safely within the environment of an operational field hospital. In conjunction with physiotherapy, this can allow service personnel to remain in theatre when they may have otherwise been returned to UK. Further large scale

prospective studies are needed to determine the efficacy of this treatment modality in an operational setting and corroborate the findings of this study.

## REFERENCES

- Cardone DA, Tallia AF. Joint and Soft Tissue Injections. *Am Fam Physician* 2002; **66**: 283-8,290.
- Kurta I, Dahir S, Dove M, Rahmatalla A. The short term effects of a single corticosteroid injection on the range of motion of the shoulder in patients with isolated acromioclavicular joint arthropathy. *Acta Orthop Belg.* 2005 Dec; **71**(6): 656-61.
- Genc H, Saracoglu M, Nacir B, Erdem HR, Kacar M. Long-term ultrasonographic follow-up of plantar fasciitis patients treated with steroid injection. *Journal Joint Bone Spine.* 2005; **72**(1): 61-5.
- Cole C, Seto C, Gazewood J. Plantar fasciitis: evidence-based review of diagnosis and therapy. *Am Fam Physician.* 2005; **72**(11): 2237-42.
- Shbeeb MI, O'Duffy JD, Michet CJ Jr, O'Fallon WM, Matteson ML. Evaluation of glucocorticosteroid injection for the treatment of trochanteric bursitis. *J Rheumatol.* 1996 Dec; **23**(12): 2104-6.
- Buchbinder R, Green S, Youd JM. Corticosteroid injections for shoulder pain. *Cochrane Database Syst Rev.* 2003;(1):CD004016.
- Buccilli TA Jr, Hall JR, Solmen JD. Sterile abscess formation following a corticosteroid injection for the treatment of plantar fasciitis. *J Foot Ankle Surg.* 2005 Nov-Dec; **44**(6): 466-8.
- Hofmeister E, Engelhardt S. Necrotizing fasciitis as complication of injection into greater trochanteric bursa. *Am J Orthop.* 2001 May; **30**(5): 426-7.
- New Zealand Guidelines Group (NZGG). The diagnosis and management of soft tissue shoulder injuries and related disorders. Wellington (NZ): New Zealand Guidelines Group (NZGG); 2004. 66 p.

10. Kerlan RK, Glousman RE. Injections and techniques in athletic medicine. *Clin Sports Med* 1989; **8**: 541-60.
11. Farooq MA, Devitt MA. Perceived efficacy and risks of infection following intra-articular injections: a survey of orthopaedic surgeons. *Ir J Med Sci*. 2005 Jan-Mar; **174**(1): 26-32.
12. Charalambous CP, Tryfonidis M, Sadiq S, Hirst P, Paul A. Septic arthritis following intra-articular steroid injection of the knee – a survey of current practice regarding antiseptic technique used during intra-articular steroid injection of the knee. *Clin Rheumatol*. 2003 Dec; **22**(6): 386-90.
13. Yun HC, Murray CK, Roop SA, Hospenhal DR *et al*. Bacteria recovered from patients admitted to a deployed US military hospital. *Mil. Medicine*. Sep 2006; **171** (9): 821-5.
14. Pfenninger JL. Joint and soft tissue aspiration and injection. In: Pfenninger JL, Fowler GC, eds. *Procedures for primary care physicians*. St. Louis: Mosby, 1994: 1036-54.