

Ruptured Distal Biceps In Military Personnel

R Hargrove, DE Griffiths, J Clasper

ABSTRACT

Early operative repair is the currently accepted treatment of distal biceps rupture. However, we describe 6 patients (with 7 ruptures), 5 of whom are in the armed forces with distal biceps tendon ruptures who, as a result of delays in presentation, were treated non-operatively. The subsequent clinical success of these patients (with three excellent, three good and one poor result), has led us to question whether the role of non-operative treatment has been underestimated within the orthopaedic, military and sports medicine literature. The more rapid rehabilitation of conservatively treated ruptures may well have implications for treatment of armed forces personnel.

Introduction

Rupture of the distal biceps tendon is rare accounting for 3% of all biceps tendon ruptures (96% long head and <1% short head) (1). The condition has been reported as early as 1843 (2) and the first description of an operative repair was by Acquaviva in 1898 (3).

Historically, the treatment of distal biceps ruptures had been conservative with early reports suggesting good function and early return to work (4, 5). In the last 30 years, however, the literature almost universally advises operative intervention for the acute rupture. The quoted rationale is that there is a loss of power in elbow flexion of about 20-30% and 40-50% in forearm supination (5,6,7). The aims of this paper are to describe our own relatively successful experience with non-operative management of this condition, to review the investigative and treatment options, suggest possible reasons for successful outcome in non-operatively treated patients, and to suggest that the faster rehabilitation of non-operative treatment may have a bearing on the treatment of military personnel in the future especially where there is a delay in presentation of the rupture.

Relevant Anatomy

The biceps muscle originates from two heads from the supraglenoid tubercle of the scapular and the coracoid process, although there may be a third or even a fourth accessory origin from the shaft of the humerus (14,15,16). The two heads join to form a

muscle belly and the distal tendon rotates 90° to insert into the radial tuberosity. It is innervated by the musculocutaneous nerve (C5,6,7) which continues to form the lateral cutaneous nerve of the forearm. A broad aponeurosis known as the lacertus fibrosus (or bicipital fascia) arises from the medial side of the distal tendon. This aponeurotic band of fibres radiates from the biceps tendon to form a triangular band passing to the ulna and merges into the deep fascia aiding in the supination of the forearm. Currently there is no effective way to image the lacertus fibrosus (even with MRI), but whether this is disrupted may have a bearing on tendon migration at the time of injury and potential recovery if the rupture is treated non-operatively.

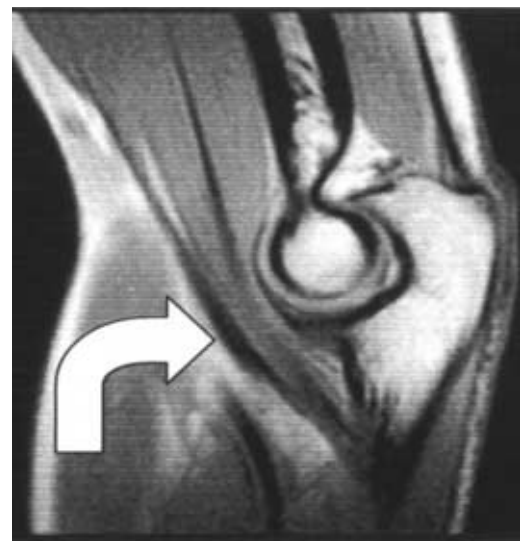

Fig 1. Normal Biceps MRI: Tendon indicated as it passes anterior to elbow joint.

Clinical Features

Distal biceps rupture is relatively rare with an incidence of approximately 1/100,000 (8). The patient is almost always male though there have been case reports of women with distal biceps ruptures (9). The injury normally occurs during contraction of the biceps with an eccentric extension force overloading the distal tendon. It commonly occurs in the dominant arm and the typical age for rupture is between 40 and 60 years old (10). This forced hyperextension against a contracting biceps tendon often occurs during sports or during accidents at work. In the sporting context this can be seen during a mistimed rugby tackle or judo throw, whilst in the workplace it often occurs when trying to transfer heavy weights or loads,

R Hargrove FRCS(Orth)
Specialist Registrar in
Trauma & Orthopaedics
Email: drhargrove@aol.com

Capt DE Griffiths
MBBS BSc RAMC
Senior House Officer in
Trauma & Orthopaedics

J Clasper DPhil DM
FRCSEd(Orth)
Consultant Orthopaedic
Surgeon

Orthopaedic
Department,
Royal Surrey County
Hospital, Guildford,
Surrey GU2 7XX

which slip or fall. Patients describe a 'pop' or a bang in the anterior of the elbow with immediate pain and loss of function. There is extensive bruising that becomes more obvious over the first few days. Elbow flexion is still possible using brachialis and the two extensor carpi radialis muscles – all of which take origin above the elbow.

Examination reveals tenderness and swelling and bruising. The significance of an intact lacertus fibrosus may be that it does not allow the muscle belly to migrate proximally with subsequent reattachment often to brachialis. But despite its apparent integrity there will always be a difference in the appearance of the two biceps muscle bellies with comparative testing against resistance. In rare cases the distal end of the ruptured tendon may be palpable.

Diagnosis of a ruptured distal biceps is predominantly a clinical observation. A good history and examination is vital. Imaging is not always considered necessary in the diagnosis of an acute traumatic rupture. However, it may be helpful in quantifying proximal migration of the distal tendon and by implication the integrity of the lacertus fibrosus. It is also helpful when dealing with chronic or partial ruptures or where the diagnosis is in doubt.

graded into 'excellent', 'good' or 'poor'. Excellent was defined as full return to work and sporting activities with no pain. Good was defined as full return to activities but with some pain or discomfort on maximal exertion. Poor was defined as being symptomatic during activities of daily living.

Of the seven ruptures, only one (Case 3a) had a poor result with conservative management. His symptoms were alleviated with an operation at 1-year post injury to decompress his musculocutaneous nerve. This patient, who had bilateral ruptures, had a good result on the other side. Three patients had an excellent result with return to full sporting activities. Two of these were able to return to rock climbing and hang gliding - Cases 2 and 4 respectively.

The final 2 patients did well with full return to normal daily activities and exercise. They reported no pain, but did report some weakness on prolonged hard physical exertion on repeated flexion and especially supination of the affected arm. The five military patients were able to continue with their military careers at the same level and were back to full active duty within 3 months from time of presentation.

Table 1. Summary of patient injuries and delays in presentation * from injury to last follow up visit.

CASE	AGE /SIDE	AETIOLOGY	DELAY IN PRESENTATION (MONTHS)	FOLLOW-UP (MONTHS)*	OUTCOME
1	54/R	Full ext. with weight	4	7	Excellent
2	47/L	Rockclimbing	12	24	Excellent
3a	37/R	Rugby tackle	12	24	Poor
3b	37/L	Lifting tyre	6	12	Good
4	58/L	Lifting heavy weight	1½	5	Excellent
5	43/R	Rugby tackle	1½	3	Good
6	62/R	Gardening accident	3	6	Good

Case Histories

Six consecutive patients were seen with delayed presentation of the rupture of the distal biceps and were managed non-operatively. One patient had bilateral ruptures. The average age was 50.2 years (37-62yrs). All were male. The delay in presentation ranged between 6 weeks and 2 years (average 8 months). Average follow up was 14 months post injury. The delays were often due to the patient not realising the importance of the injury, putting it down to a 'muscle strain'. As the patients were still able to flex the elbow and gain reasonable function after a few weeks they often wished to avoid seeing the medical team and often trained under the guidance of their PTIs (physical training instructors) or on their own. There may well have been an element of wishing to avoid being medically downgraded.

The ruptured biceps at follow-up were

Discussion

The physical activities encountered in the armed forces predispose to distal biceps tendon rupture. Paratroopers are particularly at risk when their arm gets caught up in the static line upon exit from the aircraft (11), the shoulder becomes abducted and extended and the bent forearm is forcibly extended against the line.

Military personnel are known to smoke more than the general population and according to Safran *et al.* smokers are about 7.5 times as likely to rupture their biceps as non-smokers (12). The use of steroids in weight lifters has also been implicated in biceps ruptures (13) but probably has little bearing upon the armed services.

McMaster noted that tendons tend to fail at their insertion sites rather than at their musculo-tendinous junction (17). In tendons that rupture with an intact lacertus fibrosus, there has been noted to be less

proximal migration of the tendon and this may be why a sub-group of patients do better than expected with conservative management.

Rupture of the distal biceps tendon is predominantly a clinical diagnosis, but both MRI and ultrasound have a place in the investigation of this injury (Figure 2).

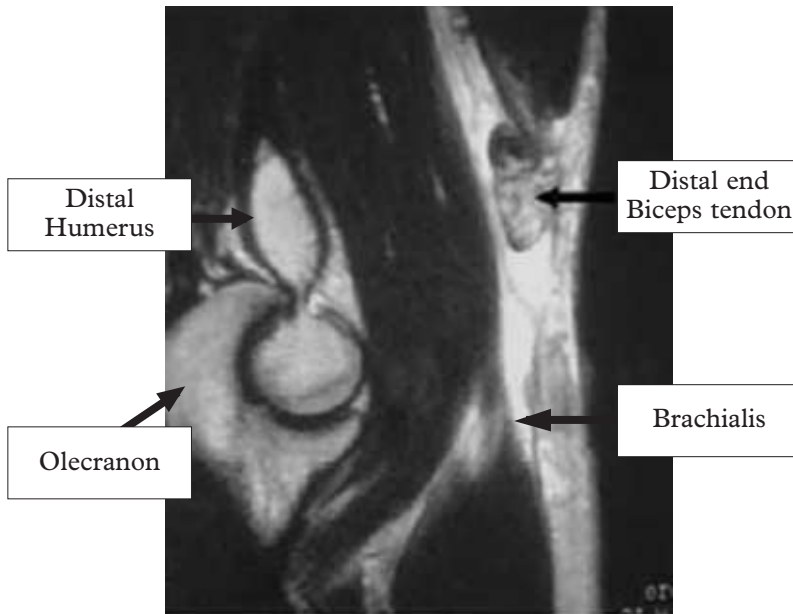


Fig 2. MRI ruptured biceps tendon.

MRI scans have been shown to be sensitive and specific for tears of the distal biceps rupture. When there is no doubt about the diagnosis clinically, some have argued that MRI is unnecessary (18). However, it is useful to distinguish between partial ruptures, which can have an insidious onset, and full ruptures, (19) as well as excluding other serious pathologies which may present with pain and swelling in the antecubital fossa (20). These include sarcomas, haemangiomas and aneurysms as well as other soft tissue tumours that may mimic biceps ruptures - the converse may also occur (21). In the future it may be possible to image the lacertus fibrosus, which if intact could have a potential bearing on the success or failure of any proposed non-operative management.

Ultrasound has been shown to be a reasonable alternative to MRI in experienced hands (22). It is cheaper than MRI and can be used to differentiate ruptures from other pathologies and is generally sensitive enough to differentiate partial from full tears (23) in the hands of an experienced musculoskeletal radiologist. Some argue that ultrasound should be the first choice investigation in a traumatic rupture (24, 25).

There are only three papers in the literature that directly compare operative and non-operative management and are widely quoted as evidence to support operative

intervention. All three are small retrospective studies where the non-operatively managed cases were self-selecting due to delays in presentation. Baker (6) described 13 patients only three of whom were treated conservatively. Kragh *et al* (26), examined operative versus non-operative results in injured paratroopers and found better results (supination power) in the operative group. There were only 3 patients in the non-operative group and 9 in the surgical group - the operative group were followed up an average of 2.2 years later while the non-operative group were followed up 11 years later. Morrey (7) compared 6 operated patients to 3 conservatively managed cases in a biomechanical study. There are no prospective comparisons of the two management strategies for primary ruptures and none at all examining delayed ruptures.

Surgical repair is far more heavily represented in the literature than conservative treatments. Since Boyd and Anderson's classic 1961 paper on the two-incision technique to fix distal biceps rupture (27), there have been muscle-splitting adaptations, single incision techniques, and variations in anchor devices such as endobuttons and mitek sutures. There are also variations in the use of brachialis, fascia lata, flexor carpi radialis or Achilles tendon allograft to augment the repair. (28-38).

Surgery is associated with significant complications such as posterior interosseous nerve palsy, radio-ulna synostosis, infection, bleeding, re-rupture, loss of rotation and heterotopic ossification (39), which can be as disabling as the original injury. Post-op rehabilitation regimes after operative repair are normally cautious - especially if there is delay in presentation. After a delayed repair we would not expect servicemen to return to full active duties before 6 months.

The implication of our small series is that in patients where there is a delay in presentation of the rupture, non-operative management may do better than the literature would suggest and have faster rehabilitation and return to work. We accept that this assumption can be criticised as the numbers are small, the study retrospective without a comparable group of surgically treated patients and the patients were self-selected by delayed presentation. It might be argued that the patients would have done even better if we had elected to operatively intervene.

While there is no doubt that good results can be obtained surgically for ruptured distal biceps tendons, the weight of evidence for poor results with non-operative treatments is sparse. In the future, it may well be possible to identify a group of patients with a ruptured tendon and an intact lacertus fibrosus who may do well with conservative management. Faster rehabilitation of non-

operatively treated ruptures may be of greater significance the military personnel when there is a delay in presentation.

Conclusion

Distal biceps tendon ruptures are serious injuries. If treated operatively they need extensive rehabilitation and it can be as much as 6 months before military personnel can return to full active service. Recent evidence in which non-operative treatment compares badly with operative treatments is weak and needs further research. Our experience suggests that in cases where there has been a delay in presentation of the ruptured distal biceps; there may be a role for considering non-operative treatment.

References

- Dobbie RP. Avulsion of the lower biceps brachii tendon. Analysis of fifty-one previously unreported cases. *Am J Surg* 1941;51:662-83.
- McReynolds IS. Avulsion of the insertion of the biceps brachii tendon and its surgical treatment. *J Bone Joint Surg Am* 1963;45:1780-1781.
- Acquaviva P. Rupture du tendon inferieur du biceps brachial droit a son insertion sur la tuberosite bicipitale, tenosuture success operatoire. *Marseille Med* 1898;35:570-573.
- Kron SD, Satinsky VP. Avulsion of the distal biceps brachii tendon. *Am J Surg*. 1954;88(4):657-9.
- Carroll RE, Hamilton LR: Rupture of the biceps brachii: A conservative method of treatment. *J Bone Joint Surg* 49A:1016,1967.
- Baker BE, Bierwagen D. Rupture of the distal tendon of the biceps brachii. Operative versus non-operative treatment. *J Bone Joint Surg Am*. 1985; 67(3):414-7.
- Morrey BF, Askew LJ, An KH, Dobyns JH. Rupture of the distal biceps tendon: biomechanical assessment of the different treatment options. *J Bone Joint Surg* 1985;67A:418-21.
- Safran MR, Graham SM. Distal biceps tendon ruptures: incidence, demographics, and the effect of smoking. *Clin Orthop*. 2002;404:275-83.
- Toczylowski HM, Balint CR, Steiner ME, Boardman M, Scheller AD Complete rupture of the distal biceps brachii tendon in female patients: a report of 2 cases. *J Shoulder Elbow Surg*. 2002;11(5):516-8.
- Bernstein AD, Breslow MJ, Jazrawi LM. Distal biceps tendon ruptures: a historical perspective and current concepts. *Am J Orthop*. 2001;30(3):193-200.
- Heckman JD, Levine MI. Traumatic closed transection of the biceps brachii in the military parachutist. *J Bone Joint Surg Am*. 1978;60(3):369-72.)
- Safran MR, Graham SM. Distal biceps tendon ruptures: incidence, demographics, and the effect of smoking. *Clin Orthop*. 2002;404:275-83.
- Davis WM, Yassine Z. An etiologic factor in the tear of the distal tendon of the biceps brachii. *J Bone Joint Surg* 1956;38A:1368.
- Ozan H, Atasever A, Sinav A, Simsek C, Basar R. An unusual insertion of accessory biceps brachii muscle. *Kaibogaku Zasshi*. 1997 Dec;72(6):515-9.
- Warner JJ, Paletta GA, Warren RF. Accessory head of the biceps brachii. Case report demonstrating clinical relevance. *Clin Orthop*. 1992 Jul;280:179-81.
- Nakatani T, Tanaka S, Mizukami S. Bilateral four-headed biceps brachii muscles: the median nerve and brachial artery passing through a tunnel formed by a muscle slip from the accessory head. *Clin Anat*. 1998;11(3):209-12.
- McMaster PE. Tendon and muscle ruptures: clinical and experimental studies on causes and locations of subcutaneous ruptures. *J Bone Joint Surg* 1933; 15:705.
- Armando F Vidal, Allen A. Biceps tendon and triceps tendon injuries. *Sports Medicine and Arthroscopy review*. 2003;11:47-56.
- Williams BD, Schweitzer ME, Weishaupt D, Lerman J, Rubenstein DL, Miller LS, Rosenberg ZS. Partial tears of the distal biceps tendon: MR appearance and associated clinical findings. *Skeletal Radiol*. 2001;30(10):560-4.
- Fitzgerald SW, Curry DR, Erickson SJ, Quinn SF, Friedman H. Distal biceps tendon injury: MR imaging diagnosis. *Radiology*. 1994;191(1):203-6.
- Qureshi SS, Puri A, Agarwal M, Merchant NH, Sheth T, Jambhekar N. Unusual late sequel of ruptured distal tendon of biceps brachii mimicking a soft-tissue tumor. *Skeletal Radiol*. 2004 May 13.
- Miller TT, Adler RS. Sonography of tears of the distal biceps tendon. *AJR Am J Roentgenol*. 2000; 175(4):1081-6.
- Belli P, Costantini M, Mirk P, Leone A, Pastore G, Marano P. Sonographic diagnosis of distal biceps tendon rupture: a prospective study of 25 cases. *J Ultrasound Med*. 2001;20(6):587-95.
- Weiss C, Mittelmeier M, Gruber G. Do we need MR images for diagnosing tendon ruptures of the distal biceps brachii? The value of ultrasonographic imaging. *Ultraschall Med*. 2000;21(6):284-6.
- Miller TT, Adler RS. Sonography of tears of the distal biceps tendon. *AJR Am J Roentgenol*. 2000; 175(4):1081-6.
- Kragh JF Jr, Basamania CJ. Surgical repair of acute traumatic closed transection of the biceps brachii. *J Bone Joint Surg Am*. 2002;84-A(6):992-8.
- Boyd MM, Anderson LD: A method of reinsertion of the distal biceps brachii tendon. *J Bone Joint Surg* 43A:1041-1043,1961.
- Ozyurekoglu T, Tsai TM. Ruptures of the distal biceps brachii tendon: results of three surgical techniques. *Hand Surg*. 2003;8(1):65-73.
- Bell RH, Wiley WB, Noble JS, Kuczynski DJ. Repair of distal biceps brachii tendon ruptures. *J Shoulder Elbow Surg*. 2000;9(3):223-6.
- Rantanen J, Orava S. Rupture of the distal biceps tendon. A report of 19 patients treated with anatomic reinsertion, and a meta-analysis of 147 cases found in the literature. *Am J Sports Med*. 1999;27(2):128-32.
- Lemos SE, Ebramzadeh E, Kvitne RS. A new technique: in vitro suture anchor fixation has superior yield strength to bone tunnel fixation for distal biceps tendon repair. *Am J Sports Med*. 2004;32(2):406-10.
- D'Alessandro DF, Shields CL Jr, Tibone JE, Chandler RW. Repair of distal biceps tendon ruptures in athletes. *Am J Sports Med*. 1993;21(1):114-9.
- El-Hawary R, Macdermid JC, Faber KJ, Patterson SD, King GJ. Distal biceps tendon repair: comparison of surgical techniques. *J Hand Surg [Am]*. 2003;28(3):496-502.
- Klonz A, Loitz D, Wohler P, Reilmann H. Rupture of the distal biceps brachii tendon: isokinetic power analysis and complications after anatomic reinsertion compared with fixation to the brachialis muscle. *J Shoulder Elbow Surg*. 2003;12(6):607-11.
- Balabaud L, Ruiz C, Nonnenmacher J, Seynaeve P, Kehr P, Rapp E. Repair of distal biceps tendon ruptures using a suture anchor and an anterior approach. *J Hand Surg [Br]*. 2004;29(2):178-82.
- Kaplan FT, Rokito AS, Birdzell MG, Zuckerman JD. Reconstruction of chronic distal biceps tendon rupture with use of fascia lata combined with a ligament augmentation device: a report of 3 cases. *J Shoulder Elbow Surg*. 2002 Nov-Dec;11(6):633-6.
- Sanchez-Sotelo J, Morrey BF, Adams RA, O'Driscoll SW. Reconstruction of chronic ruptures of the distal biceps tendon with use of an achilles tendon allograft. *J Bone Joint Surg Am*. 2002 Jun;84-A(6):999-1005.
- Bain GI, Prem H, Heptinstall RJ, Verhellen R, Paix D. Repair of distal biceps tendon rupture: a new technique using the Endobutton. *J Shoulder Elbow Surg*. 2000 Mar-Apr;9(2):120-6.
- Edward W. Kelly, M.D., Bernard F. Morrey, M.D. and Shawn W. O'Driscoll, Ph.D., M.D. Complications of Repair of the Distal Biceps Tendon with the Modified Two-Incision Technique. *JBJs (Am)* 2000;82:1575.