

References

1. United States Department of Defense Casualty Press Releases
2. U.S. Department of Defense and U.K. Ministry of Defence casualty reports compiled and reported on: www.Casualties.org
3. Alkhuzai AH, Ahmad IJ, Hweel MJ, et al. Violence-related mortality in Iraq from 2002 to 2006. *N Engl J Med*. 2008 Jan 31; 358(5):484-493.
4. Tapp C, Burke FM Jr, Wilson K, et al. Iraq War mortality estimates: A systematic review. *Confl Health*. 2008 Mar 7; 2:1.
5. Burnham G, Lafta R, Doocy S, Roberts L. Mortality after the 2003 invasion of Iraq: A cross-sectional cluster sample survey. *Lancet*. 2006 Oct 21; 368(9545):1421-1428.
6. Guha-Sapir D, van Panhuis WG. The importance of conflict-related mortality in civilian populations. *Lancet*. 2003 Jun 21; 361(9375):2126-2128.
7. McGuigan R, Spinella PC, Beekley A, et al. Pediatric trauma: Experience of a combat support hospital in Iraq. *J Pediatr Surg*. 2007 Jan; 42(1):207-210.
8. Ingari JV, Powell E. Civilian and detainee orthopaedic surgical care at an Air Force theatre hospital. *Tech Hand Up Extrem Surg*. 2007 Jun; 11(2):130-134.
9. Lopez MA, Arnholt JL. Safety of definitive in-theatre repair of facial fractures. *Arch Facial Plast Surg*. 2007; 9(6):400-405.
10. Ramasamy A, Harrison S, Lasrado I, Stewart MP. A review of casualties during the Iraqi insurgency 2006 – a British field hospital experience. *Injury*. 2009 May; 40(5):493-497.
11. Lew TA, Walker JA, Wenke JC, et al. Characterization of craniomaxillofacial battle injuries sustained by United States service members in the current conflicts of Iraq and Afghanistan. *J Oral Maxillofac Surg*. 2010 Jan; 68:3-7.
12. Powers DB, Will MW, Bourgeois SL, Hatt H. Maxillofacial treatment protocol. *J Oral Maxillofac Surg Clin North Am*. 2005 17:341
13. Brennan J. Experience of first deployed otolaryngology team in Operation Iraqi Freedom: The changing face of combat injuries. *Otolaryngol Head Neck Surg*. (2006) 134, 100-105.
14. President George W. Bush's Address to the Nation, 10 January 2007, announcing the "New Way Forward" in the conflict in Iraq by the positioning of an additional 30,000 combat troops, or "surge" in personnel assigned to Iraq. Full transcript available at: <http://www.cbsnews.com/stories/2007/01/10/iraq/main2349882.shtml>
15. Breeze J, Gibbons AJ, Opie NJ, Monaghan A. Maxillofacial injuries in military personnel treated at the Royal Centre for Defence Medicine June 2001 to December 2007. *Br J Oral Maxillofac Surg*. 2009 Nov 6. (Epub ahead of print)
16. Testimony of Lt General James G. Roudebush, Air Force Surgeon General, to the Congressional Committee of Appropriations, Subcommittee on Defense, 21 May 2009. Full transcript available at: http://appropriations.house.gov/Witness_testimony/DE/James_Roudebush_05_21_09.pdf
17. Mabry RL, Holcomb JB, Baker AM, et al. United States Army Rangers in Somalia: An analysis of combat casualties on an urban battlefield. *J Trauma*. 2000; 49(3):515-528
18. Xydakis MS, Fravell MD, Nasser KE, et al. Analysis of battlefield head and neck injuries in Iraq and Afghanistan. *Otol Head Neck Surg*. 2005 Oct; 133(4):497-504.
19. Wade AL, Dye JL, Mohrle CR, Galameau MR. Head, face and neck injuries during Operation Iraqi Freedom II: Results from the US Navy-Marine Corps Combat Trauma Registry. *J Trauma*. 2007. 63(4):836-840.
20. Owens BD, Kragh JF, Wenke JC, et al. Combat wounds in Operation Iraqi Freedom and Operation Enduring Freedom. *J Trauma*. 2008. 64(2):295-299.
21. Beebe GW, DeBakey ME. Location of hits and wounds. In *Battle Casualties*. Springfield, IL. 1952, 165-205.
22. Reister FA. Battle casualties and medical statistics: US Army Experience in the Korean War. Washington DC. The Surgeon General. Department of the Army. 1973.
23. Hardaway RM. Vietnam wound analysis. *J Trauma*. 1978. 18(9):635-643.
24. Dobson JE, Newell MJ, Shepherd JP. Trends in maxillofacial injuries in war-time (1914-1986). *Br J Oral Maxillofac Surg*. 1989. 27:441-450.
25. Eiseman B. Casualty care planning. *J Trauma*. 1979. 19(11):848-851
26. Montgomery SP, Swiecki CW, Shriver CD. The evaluation of casualties from Operation Iraqi Freedom on return to the continental United States from March to June 2003. *J Am Coll Surg*. 2005 Jul. 201(1):7-12.

Training Australian military health care personnel in the primary care of maxillofacial wounds from improvised explosive devices

Reed BE¹, Hale RG²

¹Consultant Oral and Maxillofacial Surgeon, Australian Army Reserve, 1st Health Support Battalion, John Hunter Hospital, Newcastle NSW, Australia; ²Consultant Oral and Maxillofacial Surgeon, Craniomaxillofacial Research Director, US Army Institute of Surgical Science, Brooke Army Medical Center, San Antonio, Texas, USA

Abstract

Severe facial wounds frequently result from improvised explosive devices (IEDs) as the face is still vulnerable despite advances in personal protection of soldiers. In contrast to the poor outcomes with civilian maxillofacial trauma management methods initially employed by the US Army for maxillofacial wounds from IEDs, advances in wound management methods for such injuries by the US Army have resulted in significant improvements in appearance and function. This article describes the features of a short course in the primary management of combat related maxillofacial wounds for deployed health care personnel who may not be facial specialists, including contemporary treatment techniques for those confronting wounds from IEDs which are explained in this course.

Disclaimer The views and opinions expressed herein are those of the authors and do not necessarily reflect those of the US Department of Defense or the Department of the Army or the Australian Army.

This article is based on one previously published by the authors in the Australian Defence Force Journal 2006

Introduction

Primary management or stabilization of maxillofacial trauma is a secondary task for deployed general dental officers in the Australian Army, in the absence of a deployed oral and maxillofacial surgeon. A one day course in the practical assessment and primary

management of military maxillofacial trauma, with emphasis on contemporary techniques for severe trauma from improvised explosive devices (IEDs), was introduced into the annual triservice introductory military dentistry course, and an abbreviated version provided to Army Medics, Nursing and Medical Officers.

Corresponding Author: Dr Barry Reed, Oral and Maxillofacial Surgeon, Newcastle Oral Surgery Centre, 252 Charlestown Rd Charlestown NSW 2290 Australia

Telephone: 61 2 49425888 Fax: 61 2 49425755
Email: bereed@bigpond.net.au

Information in the course was gained from liaison with US Army oral and maxillofacial surgeons at Brooke Army Medical Center, San Antonio, Texas who have deployed to Iraq and Afghanistan and from recent published US and British military experience [1-5]. The US Army has up to date expertise from the

management of approximately 6,000 maxillofacial injuries in more than 2,500 battle casualties over the last decade. A recent study of battle-injured US soldiers found 26% sustained craniomaxillofacial wounds (excluding intracranial injuries) which is significantly higher than previous wars, of which 84% were due to explosive devices [6]. Of significance, the proportions of battlefield injuries of other body regions remained constant or declined [6,7]. The course also includes the practical experience of one author (BER), an Australian Army Reserve Officer, from over 20 years of managing severe facial injuries at a civilian Australian major trauma hospital. It is carefully explained to the dental officers on the Oral and Maxillofacial Surgery (OMS) course, that while they may decide not to undertake all the procedures described by themselves, the knowledge gained regarding these techniques, in particular those for IED injuries, can provide a valuable resource when working together with their deployed medical colleagues especially in multiple casualty events. Utilising these contemporary maxillofacial techniques will significantly improve outcomes for both facial appearance and function for casualties of IEDs and ballistic injuries.

The OMS trauma course consists of illustrated lectures and laboratory sessions for practice in clinical techniques on a variety of topics. The emergency management of facial burns – especially in relation to IED wounds – and orofacial infections are also covered by the course.

Assessment of Maxillofacial IED Injuries

The assessment of suspected maxillofacial injuries includes clinical examination for signs and symptoms of facial fractures and interpretation of radiographs for suspected fractures. It is made clear that multidisciplinary assessment is essential as these casualties often have multiple injuries, with comprehensive oral and maxillofacial assessment being part of the secondary survey while assessment and emergency management of vision threatening injuries is now part of the primary survey [8]. Frequent reassessment is also vital as there is a greater risk for delayed loss of airway, occult vascular injury, intracranial penetration and other delayed complications in casualties with penetrating facial trauma as compared to blunt trauma alone [9].

Multidisciplinary care for facial wounds may include management by an ophthalmologist for all injuries that may affect vision; an otolaryngologist for loss of hearing; a neurosurgeon for traumatic brain injury, which usually results from a significant blast and penetration facial wound. It is important to remember that comprehensive facial assessment during the secondary survey should always include examination for CSF leaks, nasal septal haematomas and damage to facial nerve tracts and/or major salivary gland or ducts [3].

Pathophysiology

IED facial wounds are classified as penetration wounds [3] but may be combined with a blunt facial injury if the casualty is thrown by the blast wind against nearby solid objects, such as vehicles. In the several days after injury, tissues that initially appear normal may necrose, especially after IED facial wounds as a result of the high energy primary blast mechanism of injury; the dispersal of energy from primary ballistic projectiles; as well as secondary ballistic fragments, such as bone and teeth fragments, will further devastate the deeper facial tissues and of particular significance, the nutritive vascular structures (Figure 1). Experimental ballistic maxillofacial wounds in dogs showed that tissue loss extended for a distance of up to 30 millimetres beyond the initially visible edge of the wound [10]. This means that conventional primary closure at an initial stage may breakdown from developing deeper necrosis several days afterwards with the consequent development of

additional scarring which can compromise reconstructive surgery outcomes months afterwards [3, 11,12].

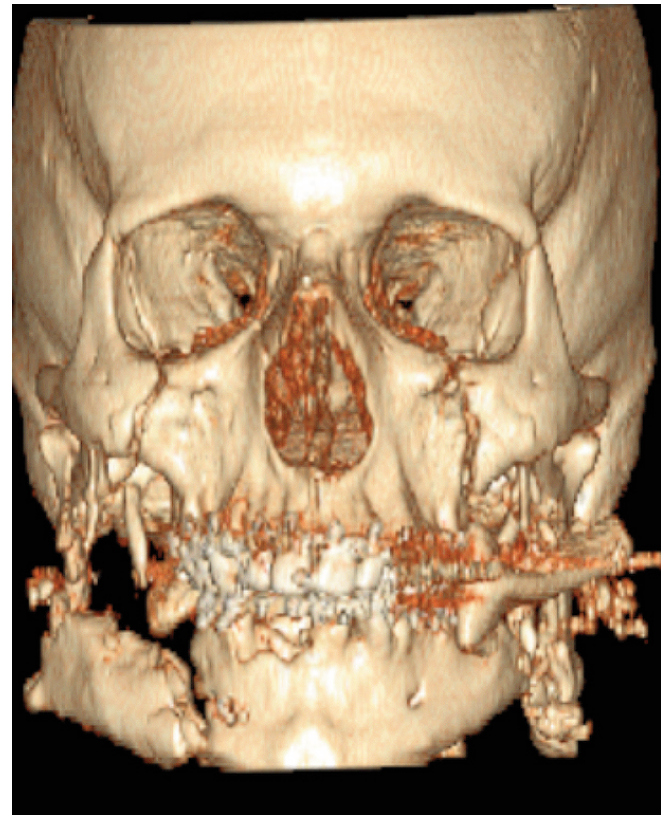


Figure 1: CT scan illustrating the complex nature and depth of ballistic fragmentation wounds due to an IED causing parafacial fractures.

Facial Soft Tissue IED Wound Management

There is usually gross contamination of IED wounds, containing rocks, dirt, grass, metal, wood, plastics, glass, animal bones, and human body parts from suicide bombings [3, 13]. These objects may also be coated in animal faeces [14]. Upon arrival in a hospital facility, antibiotics should be given for 24 hours – suitable agents are Cefazolin, Clindamycin or Ceftriaxone [15].

The two most important factors affecting ultimate facial appearance and function are avoidance of scar contracture and maximum preservation of delicate and hard to replace facial soft tissues, so that techniques to promote these outcomes are paramount [3, 4, 11,12]. This is achieved by thorough decontamination of soft tissue wounds by copious saline lavage and thorough removal of foreign bodies performed as soon as possible after injury coupled with minimum debridement (or trimming of soft tissue) in order to conserve facial tissue as much as possible (Figure 2). Decontamination is by the sponge side of a scrub brush and gauze sponges with dilute povidone iodine antiseptic [3, 13]. The Americans term this serial debridement and irrigation (D&I) and is regularly repeated until casualty evacuation; or until closure becomes indicated, which may be from two to four days later. As minimum debridement or actual trimming of tissue is also emphasised, perhaps an alternative term such as “serial decontamination and irrigation” would also be descriptive for this technique. For gross contamination with foreign bodies, the US Army has found that pulsatile lavage is the most useful technique for ensuring scrupulous wound decontamination, using battery powered, disposable pulsatile irrigation sets [3, 5] at low to medium pressure settings. If chemical contamination of the IED wound is thought possible, pulsatile decontamination as soon as possible may also be imperative to avoid mortality. Following wound irrigation, deep or avulsive wounds are packed open with

bacitracin-coated iodoform or bismuth iodoform paraffin paste ribbon gauze and changed twice daily with no closure or anastomosis of skin and mucosa at this early stage [3, 13]. Defects requiring multiple ribbon gauze packs should always have these tied together with wet to dry dressings placed over these packs. Primary closure is performed only for those wounds of superficial depth and lacking significant residual foreign body contamination after "D & I". Practice in the use of pulsatile irrigation devices and placement of ribbon gauze packs are undertaken during the instruction course.

Preservation of bone is of next importance and only very small detached fragments are removed at this stage of initial care [3]. Avulsed large fragments of bone can be stored in a surgically created subcutaneous pouch in the abdominal wall for later retrieval and reconstructive use [16]. Dental officers are made aware of this useful technique while not being expected to perform this procedure. Damaged facial nerves and salivary ducts should be identified with nylon sutures for easier discernment at later reconstruction operations.

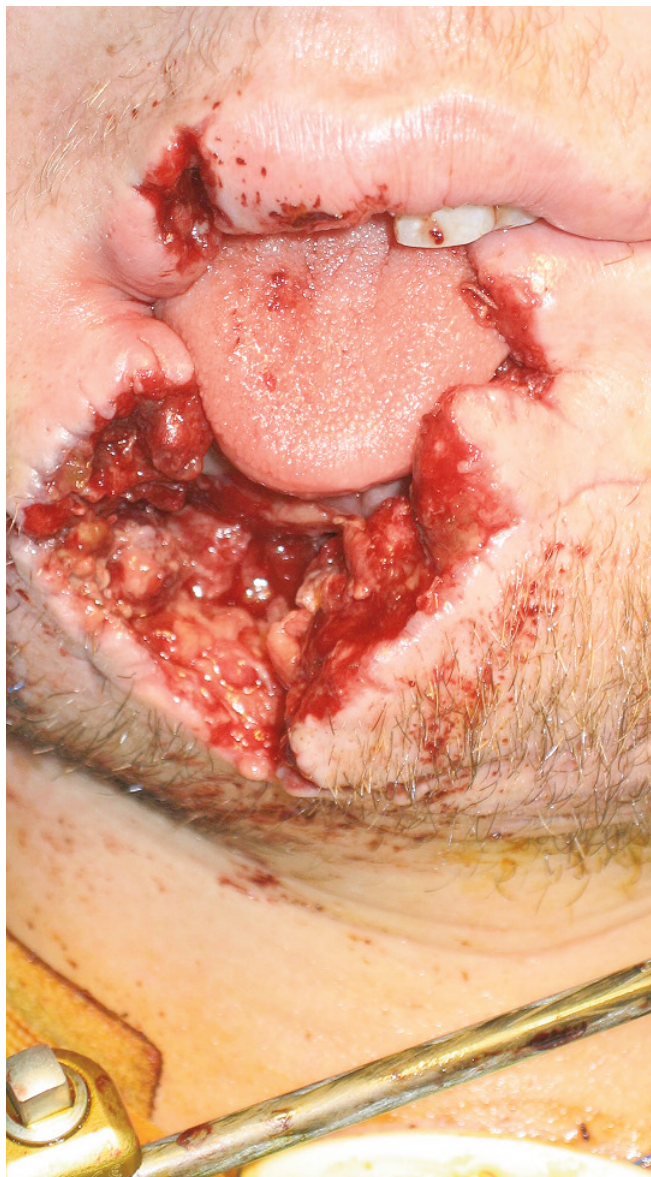


Figure 2: Contemporary methods for primary management of such an avulsive facial soft tissue IED wound are pulsatile irrigation as soon as possible, meticulous decontamination and packing with no initial primary closure. These methods promote maximum preservation of injured facial soft tissues for later reconstructive surgery

Airway Management

Assessment and maintenance of the adjacent airway takes

precedence with any maxillofacial wounds. Endotracheal intubation, or if not possible, a surgical airway are mandatory for airway threats from maxillofacial wounds such as bleeding causing obstruction. Cricothyrotomy is the emergency surgical airway of choice, rather than tracheostomy [5, 13]. Tracheostomy is undertaken later as a formal procedure before casualty evacuation.

A simplified approach to surgical cricothyrotomy utilises an elastic bougie [17]. The bougie (inside the endotracheal tube) is inserted initially through the skin and cricothyroid membrane incisions into the airway, as a guide for subsequent endotracheal tube placement. The bougie provides an excellent guide for tube placement and eliminates additional equipment, such as tracheal hooks or dilators [17]. Both the standard technique of surgical cricothyrotomy using a vertical incision [18] and the modified technique using a bougie are taught using fresh sheep specimens of the larynx and trachea with kitchen cling wrap used as an analogue for the skin layer during the dissection.

In a suspected airway burn the dictum remains "if in doubt, intubate" [13], before intubation is thwarted by increasing airway swelling [13]. The traditional use of tape to secure the endotracheal tube to the head should be discouraged as it may cause additional pressure injury as the burnt face swells further; the endotracheal tube can be fixed via simple loops of stainless steel wire to the lower incisor teeth and wire cutters secured to the bed in the event of an airway problem. A recently described alternative is an intermaxillary fixation screw inserted into the anterior mandible (or maxilla [19]) below the incisor teeth, with the wire loop around the endotracheal tube then ligated to the screw. These methods are demonstrated during the practical session on jaw wiring methods.

With airway obstruction from posteriorly displaced midfacial fractures, a definitive airway is generally indicated rather than fracture manipulation alone. If a "flail" fracture of the anterior mandible leads to potential airway obstruction from retroposition of the tongue, a 25 gauge stainless steel wire loop around the teeth adjacent to the fractures can re-establish tongue support and quickly restore the airway [13].

Facial Haemorrhage Management

Initial options for the management of severe facial haemorrhage, especially if not successful with traditional methods, have been expanded with the introduction of HemCon® and Celox™, which are extremely useful haemostatic agents. Other haemostatic products, including QuikClot® combat gauze, Hemcon ChitoFlex® dressing and 'Celox™ gauze', are very useful for initial control of haemorrhage in penetrating and otherwise inaccessible wounds as the gauzes can be easily packed deeply into such wounds. Celox™ gauze can be easily torn into small pieces for bleeding multiple puncture wounds.

Tuition in the management of epistaxis with ribbon gauze in layers, commercial nasal catheters, calcium alginate dressings ('Kaltostat') and Foley catheters is provided using plastic skull models. The placement of Foley catheters in the submandibular and floor of mouth regions for emergent control of hard to control, severe haemorrhage in penetrating ballistic maxillofacial wounds has been recently described, and is a useful maxillofacial 'damage control' technique [20]. Examples of commercial nasal packs are the Merocel Doyle's nasal dressing for anterior nasal haemorrhage control and the Epistat II nasal catheter for both anterior and posterior nasal haemorrhage control (Figure 3). These catheters are simple to insert and are effective when traditional methods fail.

Established means of control of facial and oral haemorrhage are also described ranging from less advanced packing agents such as oxidized cellulose, microfibrillar collagen, bismuth iodoform paraffin paste ribbon gauze packs, plain ribbon gauze accompanied by digital pressure and bonewax for vessels within bone (where

oxidized cellulose can also be useful) through to suture, artery forcep and titanium 'haemoclip' ligation and diathermy.

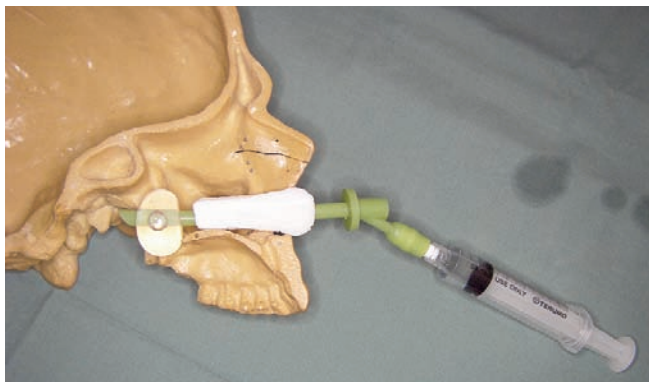


Figure 3: Laboratory session demonstration of placement of Epistat II nasal catheter using a plastic skull

Vision Threatening Injuries

Assessment and management of vision threatening injuries (VTI) are considered directly following management of life threatening injuries [8]. Maxillofacial IED injuries can result in a VTI due to orbital compartment syndrome which can be a consequence of intraorbital haemorrhage from orbital fractures or from a facial burn causing increasing intraorbital oedema and obstructing retinal blood flow. Urgent lateral canthotomy and cantholysis is indicated to prevent blindness from such a VTI [3, 5, 13]. This needs to be performed within two hours [8] or visual loss may be permanent. Lateral canthotomy and cantholysis is ideally performed by a surgeon or emergency specialist familiar with the technique, which is illustrated in the Emergency War Surgery pocketbook [21]. For the unusual case where canthotomy fails, inferolateral anterior orbitotomy performed by a surgeon is described [22].

Facial Fracture Management

If there is no threat to the airway or uncontrolled haemorrhage from facial fractures, fracture management can be deferred and is generally limited to temporary fixation if the casualty can be evacuated. Temporary fixation of fracture sites with wire (and combined with commercial arch bars if indicated) will eliminate mobile intraoral fracture sites that are open to contamination with oral fluids, which will reduce the possibility of fracture site infection and, in addition, provides superior pain control in comparison to analgesics alone without fracture fixation. Long acting bupivacaine local anaesthesia injections for fracture sites is an additional effective pain control technique. These fixation methods use either circumdental 25 gauge stainless steel wire fixation alone or sometimes combined with orthodontic elastic bands for fixation between maxilla and mandible which can be helpful for additional fracture immobilisation or external fixation using pins [3, 5, 13]. Wire intermaxillary fixation is not used as it may fatally delay emergency airway management. If stainless steel wire is unavailable, a sterilised paper clip bent into a loop between teeth at the fracture site can be utilised for simple temporary fixation [23]. Wire and arch bar fixation methods are taught in a practical session while external pin fixation is described but not taught in the course.

Conclusion

Maxillofacial IED wound management courses providing demonstrations of clinical techniques enable deploying health care personnel, who are not facial specialists, to gain clinical

proficiencies of great relevance to current conflicts. These proficiencies will result in superior aesthetic and functional results for our future wounded soldiers.

Acknowledgements

Colonel Robert G. Hale, Major Michael Gliddon and Captain Mark Ericson, Oral and Maxillofacial Surgeons, US Army, are gratefully acknowledged for their contributions to the educational program provided to the Australian Army Reserve author at Brooke Army Medical Center, San Antonio Texas.

References

1. Powers DB (ed). The role of the oral and maxillofacial surgeon in wartime, emergencies, and terrorist attacks. *Oral Maxillofacial Surg Clin N Am* 2005; Vol 17
2. Monaghan A. Maxillofacial War Surgery. British Association of Oral and Maxillofacial Surgeons Annual Scientific Meeting Lecture. Cardiff. July 2008.
3. Will MJ, Goksel T, Stone CG, Doherty MJ. Oral and maxillofacial injuries experienced in support of operation Iraqi freedom I and II. *Oral Maxillofacial Surg Clin N Am* 2005; 17: 331-339.
4. Powers DB, Will MJ, Bourgeois SL, Hatt HD. Maxillofacial trauma treatment protocol. *Oral Maxillofacial Surg Clin N Am* 2005; 17: 341-355.
5. Keith KM. Commentary: High-Energy Facial Injuries. In: Nessen SC, Lounsbury DE, Hetz SP (eds). *War Surgery in Afghanistan and Iraq. A series of cases, 2003-2007.* Office of the Surgeon General; Borden Institute Washington DC.2008. Ch 2.
6. Lew TA, Walker JA, Wenke JC, Blackbourne LH, Hale RG. Characterization of craniomaxillofacial battle injuries sustained by United States service members in the current conflicts of Iraq and Afghanistan. *J Oral Maxillofac Surg* 2010. 68:3-7.
7. Owens BD, Kragh JF, Wenke JC et al. Combat wounds in Operation Iraqi Freedom and Operation Enduring Freedom. *J Trauma* 2008. 64:295.
8. Perry M, Moutray T. Advanced Trauma Life Support (ATLS) and facial trauma: can one size fit all? Part 4: 'can the the patient see?' Timely diagnosis, dilemmas and pitfalls in the multiply injured, poorly responsive/unresponsive patient. *Int J Oral Maxillofac Surg* 2008; 37:505-514.
9. Stewart MG. Penetrating trauma to the face. In: Stewart MG. Head (eds). *Face and Neck Trauma.* Thieme. New York. 2005. Ch 21. p.195.
10. Tan YH, Zhou S, Liu Y et al. Small-vessel pathology and anastomosis following maxillofacial firearm wounds: an experimental study. *J Oral Maxillofac Surg* 1991; 49(4):348-352.
11. Kincaid B, Schmitz JP. Tissue injury and healing. *Oral Maxillofacial Surg Clin N Am* 2005; 17: 241-250.
12. Robertson BC, Manson PN. High-energy ballistic and avulsive injuries. A management protocol for the next millennium. *Surgical Clin N Am* 1999; 79:1489-1502.
13. Goksel T. Improvised explosive devices and the oral and maxillofacial surgeon. *Oral Maxillofacial Surg Clin N Am* 2005; 17: 281-287.
14. C. Lehman. Mechanisms of injury in wartime. *Rehabilitation Nursing.* Sept/Oct 2008. 33(5):192-197, 205.
15. Petersen K, Hayes DK, Blice JB, Hale RG. Prevention and management of combat-related infections of the maxillofacial, head and neck region: a review. *J Trauma* 2008; 64:S265-S276.
16. Captain John La Banc, US Navy Oral and Maxillofacial Surgeon. July 2009 during Exercise Talisman Sabre. Queensland (personal communication)
17. Macintyre A, Markarian MK, Carrison D, Coates J, Kuhls D, Fildes JJ. Three-step emergency cricothyroidotomy. *Mil Med* 2007; 172:1228-30.
18. Vissers RJ, Bair AE. Surgical airways techniques. In: Walls RM, Murphy MF (eds). *Manual of Emergency Airway Management.* Third edition. Lippincott Williams and Wilkins. Philadelphia. 2008. Ch 16.
19. Kanno T, Mitsugi M, Furuki Y, Kozato S. Endotracheal tube stabilization using an orthodontic skeletal anchor in a patient with facial burns. *Int J Oral Maxillofac Surg* 2008; 37:386-87.
20. Rezende-Neto J, Marques AC, Guedes LJ, Teixeira LZ. Damage control principles applied to penetrating neck and mandibular injury. *J Trauma* 2008; 64:1142-43.
21. Szul AC, Davis LB. *Emergency War Surgery: Third United States Revision, 2004 (Textbooks of Military Medicine).* Washington DC: Walter Reed Army Medical Center Borden Institute 2004.
22. Burkat CN, Lemke BN. Retrobulbar Hemorrhage. Inferolateral Anterior Orbitotomy for Emergent Management. *Arch Ophthalmology* 2005. 123:1260-62.
23. Walker TWM, McCann PJ. Will any wire do? Letter to the editor. *Br J Oral Maxillofac Surgery* 2009. 47:168-9.

Five months of surgery in the Multinational Field Hospital in Afghanistan with an emphasis on Oral and Maxillofacial injuries

Breeze J¹, Monaghan AM², Williams MD³, Clark RNW⁴, Gibbons AJ⁵

¹Head and Neck Clinical Research Fellow, Academic Department of Military Surgery and Trauma, Royal Centre for Defence Medicine, Birmingham Research Park, Vincent Drive, Birmingham, England, ²Consultant Oral and Maxillofacial Surgeon, Department of Maxillofacial Surgery, University Hospital Birmingham, Edgbaston, Birmingham, ³Consultant Oral and Maxillofacial Surgeon, Department of Oral and Maxillofacial Surgery, East Sussex Hospitals Trust, Kings Drive, Eastbourne, East Sussex, ⁴Consultant Oral and Maxillofacial Surgeon, Department of Oral and Maxillofacial Surgery, Royal Surrey County Hospital, Egerton Road, Guildford, ⁵Consultant Oral and Maxillofacial Surgeon, Department of Oral and Maxillofacial Surgery, Peterborough Hospital, Thorpe Road, Peterborough, Cambridgeshire.

Abstract

The aim of this review was to assess the workload of theatres in the role 3 Multinational Field Hospital in Kandahar, Afghanistan and to identify what period of day most emergency admissions arrived. During the period 05 August 2006 to 21 December 2006, 288 operations were performed on 259 patients and comprised 393 individually quantifiable procedures. 98% of these operations were to treat acute injuries. Oral and Maxillofacial surgeons were involved in 24% of operations. 63% of procedures done at these operations involved upper or lower limbs, 19% the head and neck and 18% involved the torso. An analysis of emergency admissions in November 2006 showed that most occurred between 18.00 and midnight. Although theatre timetabling made provision for this, whenever possible, elective surgery was scheduled for the following morning when emergency injury admissions were at their lowest.

Introduction

In February 2006, over 160 military personnel from the Canadian Forces Health Services deployed to Kandahar in Afghanistan to take over the existing field hospital that had been established by the American military [1]. The Canadians increased the capability of the existing hospital to two operating theatres and an intensive care unit with three beds. The ward grew in size from an initial nine beds to 15 beds by August 2006. Support facilities include a blood bank, ultrasonography, digital radiography, laboratory services and a computed tomography scanner.

The initial medical staff consisted of a general surgeon, an orthopaedic surgeon, two anaesthetists, a physician, a radiologist, and an oral and maxillofacial surgeon [2]. Although led by the Canadian Armed forces, other NATO countries, including the UK, provided staff to support the Canadians as requested. In December 2006 Canadians occupied 72 of the 120 positions [3]. The remaining staff included those from Holland, the UK, Australia, the USA and later Denmark. During the period from March 2006 to June 2006 the hospital treated 612 patients, of which 250 were operated on for battlefield related injuries. There were on average two to three Medevac cases per day [3]. From Aug 2006 to July 2007 seven British oral and maxillofacial surgeons deployed to work with this hospital. These British surgeons replaced the existing contingent of Canadian oral and maxillofacial surgeons. As well as head and neck surgery, their work included

leading, and participating in, the resuscitation of patients on arrival to the hospital and supporting, and being supported by, orthopaedic and general surgeons in theatre.

This review aimed to assess the workload of the Kandahar Field Hospital operating theatres over a five-month period with an emphasis on maxillofacial surgery and investigate the timing of emergency admissions during November 2006.

Method

During the period 05 August to 21 December 2006, four British military oral and maxillofacial surgeons worked at the Multinational Field Hospital in Kandahar. Theatre nurses collected prospective data on all operations performed within the two operating theatres. The information gathered was placed into an Excel spreadsheet and included the type of operation performed, the specialities of the surgeons and an anonymous patient identifying number.

Data from minor injuries treated in the emergency department was not included. Patients who were treated at other International and Security and Assistance Force (ISAF) hospitals in Afghanistan and then evacuated to a role 4 medical facility (Ramstein in Germany for the Canadian and US soldiers and most other ISAF personnel, Birmingham for British soldiers) without treatment at Kandahar hospital were also not included.

Data on patients admitted during November 2006 was collected from the logbook of the tactical operating cell (hospital administration and communications room). The timings of acute admissions were analysed to assess when emergency operations were most likely to be performed and hence what time of day elective operations should be done.

Corresponding Author: Major Johnno Breeze, Academic Department of Military Surgery and Trauma, Royal Centre for Defence Medicine, Birmingham B15 2SQ

Email: Email johnnobreeze@doctors.org.uk

Results

259 patients were treated during the period 05 August to 21 December 2006. 288 operations were undertaken (Table 1), comprising 393 individually quantifiable procedures. Eight patients went to theatre twice, five patients went to theatre three times, three patients went four times and one patient was treated in theatre on six occasions. 264 of the 288 operations were performed for traumatic injuries and 14 electively.

General surgeons and orthopaedic surgeons treated the majority of the patients. Maxillofacial surgeons operated in 68/288 (24%) of all operations

Specialty	Operations
General Surgery Only	108
Orthopaedic Surgery Only	103
Oral and Maxillofacial Surgery Only	42
Orthopaedic + Oral and Maxillofacial	13
General + Oral and Maxillofacial	12
General + Orthopaedic	9
General + Orthopaedics + Oral and Maxillofacial	1
Total	288

Table 1: Speciality of surgeon involved in the operation

General surgeons performed 167 procedures. 155 were performed for trauma (Table 2) and 12 performed electively. The most common traumatic operations were wound debridement (48%) and dressing changes (10%). 13 procedures were done for reasons other than trauma. These included seven appendicectomies, a haemorrhoidectomy, a vasectomy, an incision and drainage of a scrotal cyst, excision of two lipomata on the back and excision of vulvular and rectal condylomata.

Procedure	Incidence
Debridement	75
Dressing Change (Burns)	16
Laparotomy	10
Abdominal Organ Resection/ Repair	9
Appendicectomy	2
Wound Debridement (Burns)	8
Dressing Change (Non- burns)	7
Escharotomy/ Fasciotomy	7
Suturing	6
Vascular Graft/ Repair	6
Skin Grafting	5
Removal of Drain	3
Oesophageal Repair	1
Sternotomy	1
Removal of Packing	1
Embolectomy	1
Epidural Bleed Burr hole + Debridement Brain	1
Gynaecological Examination under Anaesthesia	1
Bronchoscopy	1
Gastroscopy	1
Total	155

Table 2: Procedures performed by General surgeons for trauma

Orthopaedic surgeons performed 168 operations (Table 3), all of which were undertaken to treat trauma. The most commonly performed procedures were incision and drainage (19%), placement of external fixator (15%), wound debridement (12%) and intra-medullary nailing (12%).

Procedure	Incidence
Debridement	32
Placement of External Fixator	26
Wound Debridement	20
Intra Medullary Nailing	20
Closed Reduction of Fracture (No External Fixator)	7
Open Reduction and Internal Fixation of Fracture	7
Revision of Amputation	6
Dressing Change	6
Suturing of Lacerations	5
Limb Amputation	5
Revision of Below Knee or Above Knee Amputation	4
Iliac Crest Graft	4
Nail Removal/ Revision	4
Fasciotomy	4
Removal of External Fixator	4
DCS/ DHS	3
Vascular grafting	2
Adjustment of External Fixator	2
FDL Flap	2
Insertion of Antibiotic Beads	1
Screw Removal/ Revision	1
Neurolysis	1
Tendon Transfer	1
Exploration Under Anaesthetic	1
Total	168

Table 3: Procedures performed by Orthopaedic surgeons for trauma

Maxillofacial surgeons performed 63 procedures in total. 62 were to treat traumatic injuries (Table 4), and there was a single elective procedure (removal of a pigmented lesion).

Procedure	Incidence
Wound Debridement	31
Suturing	11
Tracheostomy	9
Open Reduction and Internal Fixation of Facial Fracture	7
Placement of External Fixator	1
Removal of External Fixator	1
Manipulation Under Anaesthetic of Nasal Fracture	1
Vascular Repair	1
Total	62

Table 4: Procedures performed by Oral and Maxillofacial surgeons for trauma

The majority of the patients operated on (Table 5) were Afghan Nationals (73%) with the remainder from Canada, USA, UK, Australia and Romania (representing the coalition soldiers and civilian contract workers).

Nationality	Incidence
Afghan National Army	78
Local Afghan National	60
Afghan National Police	40
Canadian	38
US	19
Detainee	11
UK	10
Australian	2
Romanian	1
Total	259

Table 5: Nationalities of patients operated on

The non trauma procedures have been excluded. Limb injuries were operated on in 63% of procedures, the head and neck in 19% of procedures, the torso in 18% of procedures and there was a single neurosurgical procedure performed (Table 6).

Area	Incidence
Lower Limbs	40%
Upper Limbs	23%
Head and Neck	19%
Torso	18%
Brain	0.3%

Table 6: Areas of the body operated on due to trauma

The majority (n=251) of patients were treated under general anaesthesia (Table 7), the remainder (n=37) being managed through local anaesthesia, regional blocks, sedation or combinations of these methods.

Type	Incidence
General Anaesthesia	244
Local Anaesthesia only	18
Regional Block only	10
General Anaesthesia + Regional Block	7
Local Anaesthesia + Sedation	5
Sedation only	4
Total	288

Table 7: Types of anaesthesia used

An analysis of the timings of 33 hospital admissions in November 2006 (Figure 1) showed that the majority of admissions (60%) occurred between 18.00hrs and midnight. Only 14% occurred between 06.00hrs and 12.00hrs.

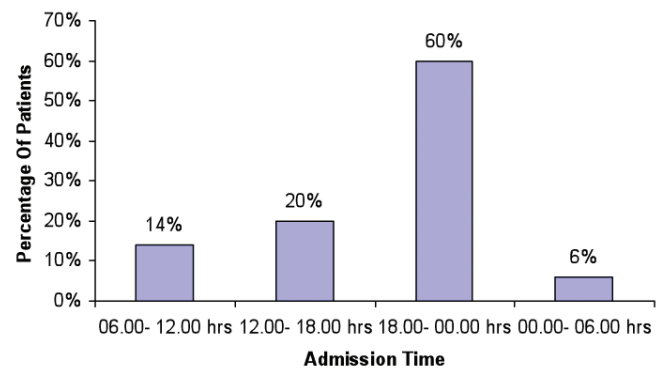


Figure 1: Timings of hospital admissions during November 2006

Discussion

Trauma registries detailing the types of injuries treated have been reported from Afghanistan. All assessed the workload of small forward surgical teams and not a larger field hospital. They treated small numbers of patients at 50 over four months, 90 over seven months and 125 patients over three months respectively [4-6]. However, out of the 125 patients [6] only 54 (43%) were operated on. The extremities were the most commonly injured body area [4, 5] and also had the most operative procedures done on them in our study. Head and neck injuries rates were given as 17% [5] and 16% [4]. In our study oral and maxillofacial surgeons operated at 24% of operations and the head and neck accounted for 19% of the body areas injured.

Comparison between studies on military trauma must be made with care as the data presented is not standardised. Our study looked at the number of operations and number of procedures to analyse the surgical workload. This does not directly equate with the incidence of injuries. Data from larger field hospitals will not account for minor wounds treated locally or those soldiers treated at forward surgical facilities and evacuated directly to a Role 4 facility.

Similar percentages of Afghan nationals were treated at 67% of operations [5], and 68% of patients [6] in comparison to our study at 73% of patients. It is important to know the nationality of patients as this affects the treatment given. Injured ISAF personnel are frequently stabilised at Kandahar before evacuation to a Role 4 facility for definitive treatment. Stable patients with injuries that do not require urgent intervention are also evacuated to a Role 4 facility for later treatment. This strategy prevents blocking a theatre slot and a ward bed that might be required for an emergency; many fractures of the facial skeleton fall in this group. As a result, the number of treated facial fractures in ISAF personnel will be much less than the actual incidence. However, lack of surgical skills and medical resources within Afghanistan's health system, dictated that most injuries to Afghan nationals required definitive treatment within the field hospital. Although this strategy covered all surgical specialties, a disproportionate number probably occurred within head and neck trauma, as to our knowledge Afghanistan did not have an oral and maxillofacial surgeon.

A further reason for returning ISAF casualties back to the country of origin for definitive treatment rather than treating them in the operational environment is the unknown microbiological flora of the hospital and its potential impact on post operative infections. Four Canadian soldiers recently injured in Afghanistan developed *A. baumannii* infection, which was subsequently resistant to numerous classes of antimicrobials [7]. The report concluded that the source of the infection was the field hospital in Kandahar.

In November 2006 the majority of admissions were between the hours of 18.00 and midnight. Most combat occurs during daylight hours but there is often delay between injury and arrival at the field hospital. Therefore, in the evening hours surgeons and anaesthetists should be available to operate or assist emergency staff when casualties arrive, and the operating theatres should be free. The Kandahar Field Hospital had a policy of undertaking elective operations between 0800hrs and 1200hrs whenever possible. This was supported by our data that showed that only 14% of emergency admissions arrived between 06.00hrs and 12.00hrs.

The head and neck region accounts for 12% of the total body surface area. Data from military conflicts in the second half of the 20th century indicate that approximately 16% of battlefield injuries involve the head and neck [8, 9]. Reviews from Iraq and Afghanistan since 2003 have reported rates of 16% [10] to 20% [11] and 21% [12]. This is most likely due to improvement in body armour resulting in less thoraco- abdominal injuries [12] as well as the changing nature of weapons used. Nevertheless, in our study the majority of patients were Afghan Nationals and although some police and military would have worn body armour the majority would not.

Debridement of wounds was the most common operation done by all surgical specialities. A head and neck team deployed to Iraq for 4 months in 2004 [13] performed 257 operative procedures. They also found that the vast majority of operations involved soft tissue debridement, exploration and repair.

Twenty four percent of procedures were performed by dually qualified Oral and Maxillofacial surgeons. Extended competencies allowed them to work with the general and orthopaedic surgeons on ophthalmic, burns and neurosurgery cases. Developing a broad range of surgical skills is an important aspect of military Oral and Maxillofacial training [14].

Our study gives baseline retrospective data of the workload of theatres in a Role 3 hospital in Afghanistan. It is hoped that prospective data collection on future deployments will allow comparisons to be made and trends and changes to be identified.

References

1. Tien H, Farrell R, Macdonald J. Preparing Canadian military surgeons for Afghanistan. *J Can Med Assoc* 2006; **175(11)**: 1365
2. Haberstock M. A year in the life of the Canadian Forces Health Services (Editorial). *Can Med Assoc J* 2006; **175(11)**: 1345-1347
3. Kelly G. Medical professionals provide a full spectrum care. *Canadian Forces Health Services Group Bulletin* 2006; **7(10)**: 23-24
4. Place R J, Rush R M, Arrington E D. Forward surgical team (FST) workload in a special operations environment: the 250th FST in Operation ENDURING FREEDOM. *J Trauma* 2006; **61(2)**: 256- 260
5. Beekley A C, Watts D M. Combat trauma experience with the United States Army 102nd Forward Surgical Team in Afghanistan. *Am J Surg* 2004; **187(5)**: 652- 654
6. Acosta J A, Hatzigeorgiou C, Smith L S. Developing a trauma registry in a forward deployed military hospital: Preliminary report. *J Trauma* 2003; **54(3)**: 814- 821
7. Tien H C, Battad A, Bryce E A, et al Multi-drug resistant *Acinetobacter* infections in critically injured Canadian forces soldiers. *BMC Infectious Diseases* 2007; **7**: 95
8. Jackson DS, Batty CG, Ryan JM, McGregor WS. The Falklands War: Army Field Surgical Experience. *Ann R Coll Surg Eng* 1983; **65**: 281-285
9. Dobson JE, Newell MJ, Shepherd JP. Trends in Maxillofacial Injuries in Wartime (1914-1986). *Br J Oral Maxillofac Surg* 1989; **27**: 441-450
10. Montgomery S P, Swiecki C W, Shriver C D. The evaluation of casualties from Operation Iraqi Freedom on return to the continental United States from March to June 2003. *J Am Coll Surg* 2005; **201**: 7-13
11. Roberts P (editor). *The British Military Surgery Pocket Book*. British Army Publication 2004
12. Xydakis MS, Fravel MD, Casler JD. Analysis of Battlefield head and Neck Injuries in Iraq and Afghanistan. *Otol Head and Neck Surg* 2005; **133**: 497- 504
13. Brennan J. Experience of first deployed otolaryngology team in Operation Iraqi Freedom: the changing face of combat injuries. *Otolaryngol Head Neck Surg* 2006; **134(1)**: 100- 105
14. Gibbons AJ, Baden JM, Williams MD. Oral and maxillofacial surgery. *J R Army Med Corps* 2004; **150(3)**: 205- 207